

Ankur
Gupta



BA Continuum India Pvt. Ltd.
A nonbank subsidiary of Bank of America Corporation



भारत निर्वाचन आयोग
पहचान पत्र

ELECTION COMMISSION OF INDIA
IDENTITY CARD

TPU0293241



निर्वाचक का नाम : अंकुर गुप्ता
Elector's Name : Ankur Gupta
पिता का नाम : रत्न लाल गुप्ता
Father's Name : Ram Lal Gupta
लिंग / Sex : पुरुष / Male
1.1.2012 को आयु : 20
Age as on 1.1.2012

CERTIFICATE OF MEDICAL FITNESS

This is to certify that I have conducted the clinical examination

of Ankur Gupta on _____

After reviewing the medical history and on clinical examination it has been found that he/she is

	Tick
<ul style="list-style-type: none"> • Medically Fit 	<input type="checkbox"/>
<ul style="list-style-type: none"> • Fit with restrictions/recommendations <p>Though following restrictions have been revealed, in my opinion, these are not impediments to the job.</p> <p>1. <u>Mild dyslipidemia</u></p> <p>2. <u>Abnormal LFT (↑ S. Bilirubin)</u></p> <p>3. <u>Absent Rt. Kidney</u></p> <p>However the employee should follow the advice/medication that has been communicated to him/her.</p> <p>Review after <u>15 d</u></p>	<input type="checkbox"/>
<ul style="list-style-type: none"> • Currently Unfit. Review after _____ recommended 	<input type="checkbox"/>
<ul style="list-style-type: none"> • Unfit 	<input type="checkbox"/>

Dr. Ankur Gupta
 Medical Officer
 The Apollo Clinic, (Location)
DR. ASHOK K. GUPTA
MBBS, MD
Consulting Physician
Regd. No. 7513 (HMC)

This certificate is not meant for medico-legal purposes.

उपलब्ध ओ.पी.डी. सुविधाएँ

- हृदय रोग चिकित्सा
(Cardiology)
- बाल एवं भ्रूण रोग चिकित्सा
(Paediatrics & Fetal Medicine)
- बाल रोग चिकित्सा
(Paediatrics)
- स्त्री रोग चिकित्सा
(Gynaecology)
- हड्डी रोग चिकित्सा
(Orthopaedics)
- दन्त चिकित्सा
(Dental Care)
- सामान्य चिकित्सा
(General Physician)
- फिजियोथैरेपी
(Physiotherapy)
- चर्म रोग चिकित्सा
(Dermatology)
- मूत्र रोग चिकित्सा
(Urology)
- गुर्दा रोग चिकित्सा
(Nephrology)

उपलब्ध जाँच

- डायलिसिस (Dialysis)
- अल्ट्रासाउण्ड (Ultrasound)
- ईको (Echo)
- स्ट्रेस ईको (Stress Echo)
- टी.एम.टी. (T.M.T.)
- पी.एफ.टी. (Lung Function Test)
- ई.सी.जी. (E.C.G.)
- ई.ई.जी. (E.E.G.)
- एक्स-रे (X-Ray)
- मैमोग्राफी (Mammography)
- ओ.पी.जी. (Dental X-Ray)
- हॉल्टर टेस्ट (Holter Test)

Ref. No.:.....

Date:.....

Name of patient: Mr. Ankur Gupta	Age: 27	M/F: M
Consultant:	Speciality: Package	
MR No : MR008288	Visit No: OP017403	Date: 12-06-2019

Ht = 5'6"
Wt = 71 kg
PR = 74/mnt
Bp = 110/60 mmHg
Chest |
CVS |
Abd |

Not for Medico Legal Purpose

खून एवं मल-मूत्र की जाँच NABL द्वारा मान्यता प्राप्त MoIQ लैब द्वारा की जाती है।

सम्पर्क सूत्र: 0124-2224102 / 103 / 104 | Mob.: 8683061905, 8683061906

ओ.पी.डी. पर्ची का शुल्क केवल तीन दिन के लिए मान्य रहेगा।

Radiology Report

Name : Mr. Ankur Gupta
Age/Gender : 27 Y/M
Prescribed Doctor : Self

MR No : MR008288
Visit ID : OP017403
Report Date : 12-06-2019 10:13

Ultrasound

USG EXAMINATION : WHOLE ABDOMEN

Liver shows normal shape and size with homogenous echo texture. Intrahepatic biliary radicals are not dilated. No focal lesion is seen. **Portal Vein** shows normal calibre.

Gall bladder shows physiological distension and normal wall thickness. No calculus or mass is seen in the lumen.

CBD is normal in diameter. No calculus is seen

Pancreas is normal in size, shape and echo texture.

Spleen is normal in shape, size and echo texture.

Right kidney is not visualized in right renal fossa region (Known case of absent right kidney).

Left kidney is enlarged in size. Cortico-medullary differentiation is maintained. Left kidney show no calculus or hydronephrosis. Left kidney measures 10 x 9cm.


No free fluid is seen in the intra-peritoneal cavity. No evidence of mesenteric lymphadenopathy is seen.

Urinary bladder is normal in shape, size and wall thickness. No mass or calculus is seen.

Prostate is normal in shape, size & echo texture.

IMP: Absent right kidney with compensatory hypertrophy of left kidney.

Adv:- Clinical correlation and further evaluation.


Dr. Pawan Joon
MD (Radio- diagnosis)

Radiology Report

Name : Mr. Ankur Gupta
Age/Gender : 27 Y/M
Prescribed Doctor : Self

MR No : MR008288
Visit ID : OP017403
Report Date : 12-06-2019 15:03

X-Ray

X-RAY CHEST PA VIEW

Bilateral lung fields appears to be clear. No obvious pulmonary parenchymal lesion is seen.

Trachea is central.

Cardiac configuration appears to be normal with normal cardio-thoracic ratio.

Both costo phrenic angles and domes of diaphragm are normal.

Visualized soft tissue and bony thoracic cage appears to be normal.

Scoliosis is seen in involving thoracic spine with convexity towards right side.

Clinical correlation & further evaluation.



DR. PAWAN JOON
MD (Radio-diagnosis)

VIVEKANAND AROGYA KENDRA

Patient Details **Date:** 04-Jan-80 **Time:** 12:49:11 PM
Name: ANKUR GUPTA ID: MR008288
Age: 27 y **Sex:** M **Height:** 56 cms **Weight:** 71 Kgs
Clinical History: NOTHING SIGNIFICANT

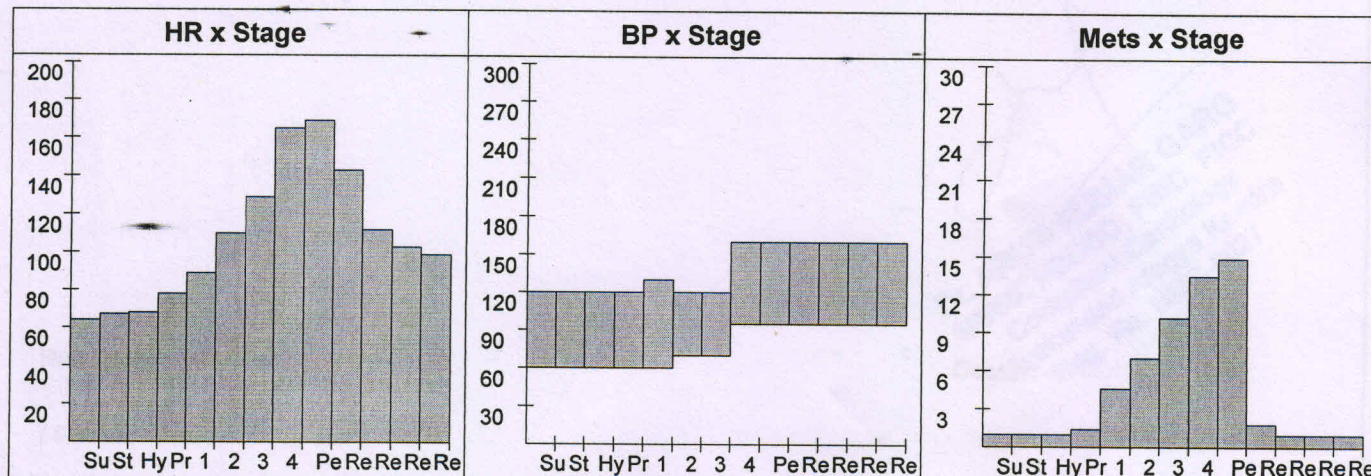
Medications: NIL

Test Details

Protocol: Bruce **Pr.MHR:** 193 bpm **THR:** 173 (90 % of Pr.MHR) bpm
Total Exec. Time: 12 m 24 s **Max. HR:** 169 (88% of Pr.MHR)bpm **Max. Mets:** 14.90
Max. BP: 160 / 95 mmHg **Max. BP x HR:** 27040 mmHg/min **Min. BP x HR:** 3840 mmHg/min
Test Termination Criteria: THR achieved

Protocol Details

Stage Name	Stage Time (min : sec)	Mets	Speed (mph)	Grade (%)	Heart Rate (bpm)	Max. BP (mm/Hg)	Max. ST Level (mm)	Max. ST Slope (mV/s)
Supine	0 : 31	1.0	0	0	64	120 / 60	-0.64 aVR	1.77 V3
Standing	0 : 35	1.0	0	0	67	120 / 60	-0.64 aVR	1.77 V3
Hyperventilation	0 : 13	1.0	0	0	68	120 / 60	-0.64 aVR	1.42 V3
1	3 : 0	4.6	1.7	10	89	130 / 60	-1.70 III	2.83 V3
2	3 : 0	7.0	2.5	12	110	120 / 70	-1.27 aVR	2.83 V3
3	3 : 0	10.2	3.4	14	129	120 / 70	-3.40 V2	-5.31 V2
4	3 : 0	13.5	4.2	16	165	160 / 95	-5.94 V2	4.95 V3
Peak Ex	0 : 24	14.9	5	18	169	160 / 95	-1.27 V5	5.66 V3
Recovery(1)	1 : 0	1.8	1	0	143	160 / 95	-2.12 aVR	5.66 V3
Recovery(2)	1 : 0	1.0	0	0	112	160 / 95	-1.91 aVR	5.66 V3
Recovery(3)	1 : 0	1.0	0	0	103	160 / 95	-1.49 aVR	5.66 V3
Recovery(4)	0 : 18	1.0	0	0	99	160 / 95	-1.27 aVR	3.18 V3



VIVEKANAND AROGYA KENDRA

Patient Details

Date: 04-Jan-80

Time: 12:49:11 PM

Name: ANKUR GUPTA ID: MR008288

Age: 27 y

Sex: M

Height: 56 cms

Weight: 71 Kgs


Interpretation

No significant ST-T changes seen during stress TMT.
TMT is negative for stress induced myocardial ischemia seen.
Please correlate clinically.

Ref. Doctor: -----

(Summary Report edited by user)

Doctor: -----


Dr. ARUN KUMAR GARG
MBBS, PGDCC, FNIC, FICC
Consultant Cardiology
Vivekanand Arogya Kendra
Reg. No. HMC-8027