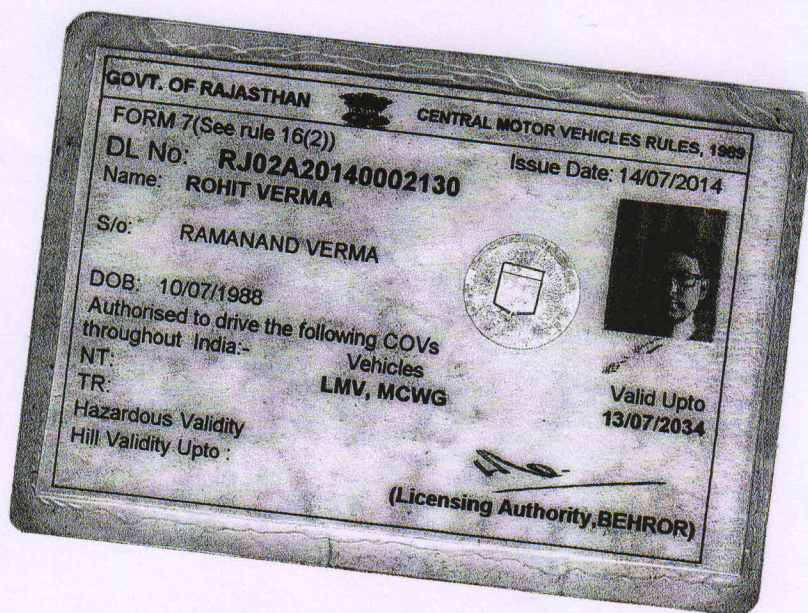
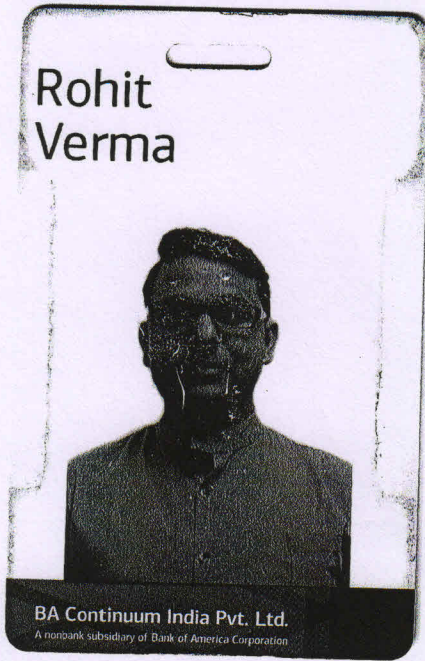
## CERTIFICATE OF MEDICAL FITNESS

This is to certify that I have conducted the clinical examination

of Rohit Verma on \_\_\_\_\_

After reviewing the medical history and on clinical examination it has been found that he/she is

	Tick
<ul style="list-style-type: none"> <li>• Medically Fit</li> </ul>	<input type="checkbox"/>
<ul style="list-style-type: none"> <li>• Fit with restrictions/recommendations</li> </ul> <p>Though following restrictions have been revealed, in my opinion, these are not impediments to the job.</p> <p>1. <u>Dyslipidemia with Mild hyperuricemia</u></p> <p>2. <u>Mild M/H Anaemia</u></p> <p>3. <u>Abnormal LFT - Raised S.Bil + Enzymes</u></p> <p>However the employee should follow the advice/medication that has been communicated to him/her.</p> <p>Review after <u>15 d</u></p>	<input type="checkbox"/>
<ul style="list-style-type: none"> <li>• Currently Unfit. Review after _____ recommended</li> </ul>	<input type="checkbox"/>
<ul style="list-style-type: none"> <li>• Unfit</li> </ul>	<input type="checkbox"/>

Dr. AJG  
 Medical Officer  
 The Apollo Clinic, (Location)

**Dr. ASHOK K. GUPTA**  
 MBBS, MD  
 Consulting Physician  
 Regd. No. 7513 (HMC)

*This certificate is not meant for medico-legal purposes*

## उपलब्ध ओ.पी.डी. सुविधाएँ

- ☑ हृदय रोग चिकित्सा  
(Cardiology)
- ☑ बाल एवं भ्रूण रोग चिकित्सा  
(Paediatrics & Fetal Medicine)
- ☑ बाल रोग चिकित्सा  
(Paediatrics)
- ☑ स्त्री रोग चिकित्सा  
(Gynaecology)
- ☑ हड्डी रोग चिकित्सा  
(Orthopaedics)
- ☑ दन्त चिकित्सा  
(Dental Care)
- ☑ सामान्य चिकित्सा  
(General Physician)
- ☑ फिजियोथैरेपी  
(Physiotherapy)
- ☑ चर्म रोग चिकित्सा  
(Dermatology)
- ☑ मूत्र रोग चिकित्सा  
(Urology)
- ☑ गुर्दा रोग चिकित्सा  
(Nephrology)

## उपलब्ध जाँच

- ☑ डायलिसिस (Dialysis)
- ☑ अल्ट्रासाउण्ड (Ultrasound)
- ☑ ईको (Echo)
- ☑ स्ट्रेस ईको (Stress Echo)
- ☑ टी.एम.टी. (T.M.T.)
- ☑ पी.एफ.टी. (Lung Function Test)
- ☑ ई.सी.जी. (E.C.G.)
- ☑ ई.ई.जी. (E.E.G.)
- ☑ एक्स-रे (X-Ray)
- ☑ मैमोग्राफी (Mammography)
- ☑ ओ.पी.जी. (Dental X-Ray)
- ☑ हॉल्टर टेस्ट (Holter Test)

Ref. No.:.....

Date:.....

<b>Name of patient:</b> Mr. Rohit Verma	<b>Age:</b> 31	<b>M/F:</b> M
<b>Consultant:</b>	<b>Speciality:</b> Package	
<b>MR No :</b> MR008287	<b>Visit No:</b> OP017401	<b>Date:</b> 12-06-2019

Ht = 5'4"  
Wt = 70.6 Kg  
Hb = 84 gm/L  
Bp = 130/90 mm Hg  
Chesty  
CNS normal  
Abd -

Not for Medico Legal Purpose

खून एवं मल-मूत्र की जाँच NABL द्वारा मान्यता प्राप्त MoIQ लैब द्वारा की जाती है।

सम्पर्क सूत्र: 0124-2224102 / 103 / 104 | Mob.: 8683061905, 8683061906

ओ.पी.डी. पर्ची का शुल्क केवल तीन दिन के लिए मान्य रहेगा।

## Radiology Report

Name : Mr. Rohit Verma

MR No : MR008287

Age/Gender : 31 Y/M

Visit ID : OP017401

Prescribed Doctor : Self

Report Date : 12-06-2019 10:46

## Ultrasound

### USG EXAMINATION : WHOLE ABDOMEN

**Liver** shows normal shape and size with homogenous echo texture. Intrahepatic biliary radicals are not dilated. No focal lesion is seen. **Portal Vein** shows normal calibre.

**Gall bladder** shows physiological distension and normal wall thickness. No calculus or mass is seen in the lumen.

**CBD** is normal in diameter. No calculus is seen

**Pancreas** is normal in size, shape and echo texture.

**Spleen** is normal in shape, size and echo texture.

**Right kidney** show normal shape & size. Cortico-medullary differentiation is maintained. Right kidney show no calculus or hydronephrosis.

**Left kidney** show normal shape & size. Cortico-medullary differentiation is maintained. Left kidney show no calculus or hydronephrosis.


No free fluid is seen in the intra-peritoneal cavity. No evidence of mesenteric lymphadenopathy is seen.

**Urinary bladder** is normal in shape, size and wall thickness. No mass or calculus is seen.

**Prostate** is normal in shape, size & echo texture. Volume of prostate is 15.2cc.

**IMP: Normal study.**

PLEASE CORRELATE CLINICALLY.

  
Dr. Pawan Joon  
MD (Radio-diagnosis)

## Radiology Report

Name : Mr. Rohit Verma  
Age/Gender : 31 Y/M  
Prescribed Doctor : Self

MR No : MR008287  
Visit ID : OP017401  
Report Date : 12-06-2019 15:00

## X-Ray

### X-RAY CHEST PA VIEW

Bilateral lung fields appears to be clear. No obvious pulmonary parenchymal lesion is seen.


Trachea is central.

Cardiac configuration appears to be normal with normal cardio-thoracic ratio.

Both costo phrenic angles and domes of diaphragm are normal.

Visualized soft tissue and bony thoracic cage appears to be normal.

PLEASE CORRELATE CLINICALLY.



DR. PAWAN JOON  
MD (Radio-diagnosis)

# VIVEKANAND AROGYA KENDRA

**Patient Details**                      **Date:** 04-Jan-80                      **Time:** 11:41:31 AM  
**Name:** ROHIT VERMA ID: MR008287  
**Age:** 31 y                                      **Sex:** M                                      **Height:** 54 ins                                      **Weight:** 71 Kgs  
**Clinical History:** NOTHING SIGNIFICANT

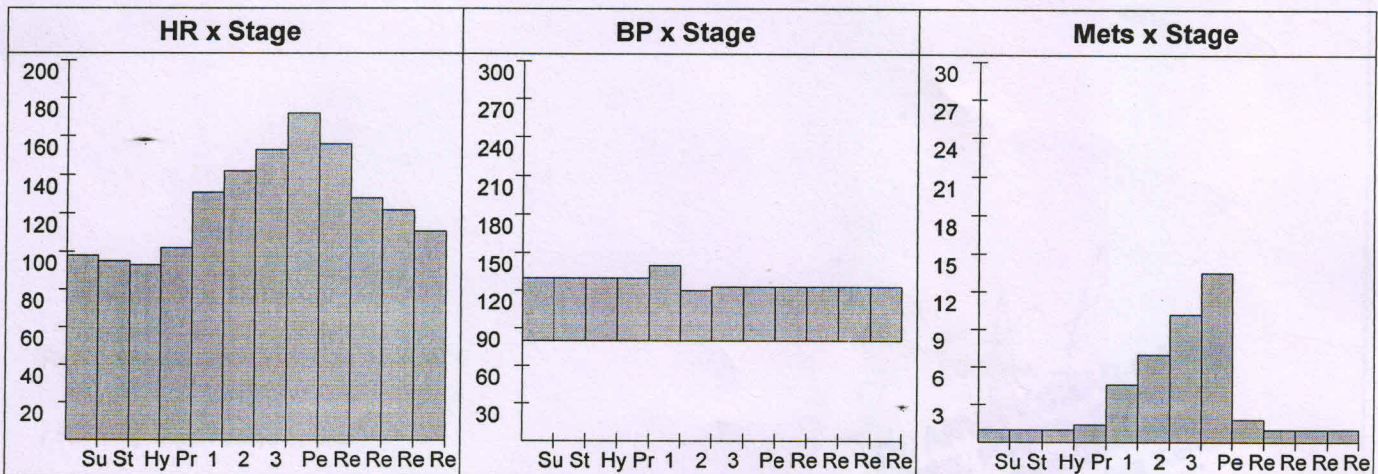
**Medications:** NIL

## Test Details

**Protocol:** Bruce                                      **Pr.MHR:** 189 bpm                                      **THR:** 170 (90 % of Pr.MHR) bpm  
**Total Exec. Time:** 10 m 13 s                      **Max. HR:** 172 ( 91% of Pr.MHR )bpm                      **Max. Mets:** 13.50  
**Max. BP:** 140 / 80 mmHg                      **Max. BP x HR:** 24080 mmHg/min                      **Min. BP x HR:** 7440 mmHg/min  
**Test Termination Criteria:** THR achieved

## Protocol Details

Stage Name	Stage Time (min : sec)	Mets	Speed (mph)	Grade (%)	Heart Rate (bpm)	Max. BP (mm/Hg)	Max. ST Level (mm)	Max. ST Slope (mV/s)
Supine	0 : 41	1.0	0	0	98	130 / 80	-1.06 aVR	1.42 II
Standing	0 : 17	1.0	0	0	95	130 / 80	-1.06 aVR	1.42 II
Hyperventilation	0 : 15	1.0	0	0	93	130 / 80	-0.85 aVR	1.42 II
1	3 : 0	4.6	1.7	10	131	140 / 80	-1.06 aVR	1.77 II
2	3 : 0	7.0	2.5	12	142	120 / 80	-1.06 aVR	2.48 V2
3	3 : 0	10.2	3.4	14	153	123 / 80	-1.27 aVR	3.54 V3
Peak Ex	1 : 13	13.5	4.2	16	172	123 / 80	-1.91 V5	-4.95 V5
Recovery(1)	1 : 0	1.8	1	0	156	123 / 80	-1.91 V5	5.66 V3
Recovery(2)	1 : 0	1.0	0	0	128	123 / 80	-1.49 aVR	5.66 V3
Recovery(3)	1 : 0	1.0	0	0	122	123 / 80	-1.27 aVR	4.95 V3
Recovery(4)	0 : 27	1.0	0	0	111	123 / 80	-0.85 aVR	2.48 V3



# VIVEKANAND AROGYA KENDRA

## Patient Details

Date: 04-Jan-80

Time: 11:41:31 AM

Name: ROHIT VERMA ID: MR008287

Age: 31 y

Sex: M

Height: 54 ins

Weight: 71 Kgs


## Interpretation

No significant ST-T changes seen during stress testing.  
TMT is negative for stress induced myocardial ischemia seen.  
Please correlate clinically.

Ref. Doctor: -----

Doctor: -----

( Summary Report edited by user )

  
**Dr. ARUN KUMAR GARG**  
MBBS, PGDCC, FNIC, FICC  
Consultant Cardiology  
Vivekanand Arogya Kendra  
Reg. No. MIC-8027