

Praveen  
Rathor



BA Continuum India Pvt. Ltd.  
A nonbank subsidiary of Bank of America Corporation

## CERTIFICATE OF MEDICAL FITNESS

This is to certify that I have conducted the clinical examination

of Praveen Raturi on \_\_\_\_\_

After reviewing the medical history and on clinical examination it has been found that he/she is

<ul style="list-style-type: none"> <li>• Medically Fit</li> </ul>	Tick
<ul style="list-style-type: none"> <li>• Fit with restrictions/recommendations</li> </ul> <p>Though following restrictions have been revealed, in my opinion, these are not impediments to the job.</p> <p>1. <u>Mild dyslipidemia</u></p> <p>2. <u>USG - Fatty liver Gr I</u></p> <p>3. _____</p> <p>However the employee should follow the advice/medication that has been communicated to him/her.</p> <p>Review after <u>6m</u></p>	
<ul style="list-style-type: none"> <li>• Currently Unfit. Review after _____ recommended</li> </ul>	
<ul style="list-style-type: none"> <li>• Unfit</li> </ul>	

Dr. ASHOK K. GUPTA  
 Medical Officer  
 The Apollo Clinic, (Location)

**Dr. ASHOK K. GUPTA**  
**MBBS, MD**  
 Consulting Physician  
 Regd. No. 7513 (HMC)

*This certificate is not meant for medico-legal purposes*

## उपलब्ध ओ.पी.डी. सुविधाएँ

- हृदय रोग चिकित्सा  
(Cardiology)
- बाल एवं भ्रूण रोग चिकित्सा  
(Paediatrics & Fetal Medicine)
- बाल रोग चिकित्सा  
(Paediatrics)
- स्त्री रोग चिकित्सा  
(Gynaecology)
- हड्डी रोग चिकित्सा  
(Orthopaedics)
- दन्त चिकित्सा  
(Dental Care)
- सामान्य चिकित्सा  
(General Physician)
- फिजियोथैरेपी  
(Physiotherapy)
- चर्म रोग चिकित्सा  
(Dermatology)
- मूत्र रोग चिकित्सा  
(Urology)
- गुर्दा रोग चिकित्सा  
(Nephrology)

## उपलब्ध जाँच

- डायलिसिस (Dialysis)
- अल्ट्रासाउण्ड (Ultrasound)
- ईको (Echo)
- स्ट्रेस ईको (Stress Echo)
- टी.एम.टी. (T.M.T.)
- पी.एफ.टी. (Lung Function Test)
- ई.सी.जी. (E.C.G.)
- ई.ई.जी. (E.E.G.)
- एक्स-रे (X-Ray)
- मैमोग्राफी (Mammography)
- ओ.पी.जी. (Dental X-Ray)
- हॉल्टर टेस्ट (Holter Test)

Not for Medico Legal Purpose

Ref. No.: .....

Date: .....

<b>Name of patient:</b> Mr. PRAVEEN RATHOR	<b>Age:</b> 33	<b>M/F:</b> M
<b>Consultant:</b>	<b>Speciality:</b> Package	
<b>MR No :</b> MR008176	<b>Visit No:</b> OP017155	<b>Date:</b> 10-06-2019

Ht 163 cm  
wt = 68.5 kg  
BP 96/110  
BP < 130/110 mm Hg  
Chest  
CVS / N  
Abd / N

खून एवं मल-मूत्र की जाँच NABL द्वारा मान्यता प्राप्त MoIQ लैब द्वारा की जाती है।

सम्पर्क सूत्र: 0124-2224102 / 103 / 104 | Mob.: 8683061905, 8683061906

ओ.पी.डी. पर्ची का शुल्क केवल तीन दिन के लिए मान्य रहेगा।

## Radiology Report

Name : Mr. PRAVEEN RATHOR  
Age/Gender : 33 Y/M  
Prescribed Doctor : Self

MR No : MR008176  
Visit ID : OP017155  
Report Date : 10-06-2019 09:50

## Ultrasound

### USG EXAMINATION : WHOLE ABDOMEN

**Liver** shows normal shape and size **with mildly increased echogenicity, suggestive of fatty change.** Intrahepatic biliary radicals are not dilated. No focal lesion is seen. **Portal Vein** shows normal calibre. **Gall bladder** shows physiological distension and normal wall thickness. No calculus or mass is seen in the lumen.

**CBD** is normal in diameter. No calculus is seen

**Pancreas** is normal in size, shape and echo texture.

**Spleen** is normal in shape, size and echo texture.

**Right kidney** show normal shape & size. Cortico-medullary differentiation is maintained. Right kidney show no calculus or hydronephrosis.

**Left kidney** show normal shape & size. Cortico-medullary differentiation is maintained. Left kidney show no calculus or hydronephrosis.


No free fluid is seen in the intra-peritoneal cavity. No evidence of mesenteric lymphadenopathy is seen.

**Urinary bladder** is normal in shape, size and wall thickness. No mass or calculus is seen.

**Prostate** is normal in shape, size & echo texture. Volume of prostate is 10.7cc.

**Imp:- Fatty liver grade I.**

PLEASE CORRELATE CLINICALLY.

  
Dr. Pawan Joon  
MD ( Radio- diagnosis)

## Radiology Report

Name : Mr. PRAVEEN RATHOR  
Age/Gender : 33 Y/M  
Prescribed Doctor : Self

MR No : MR008176  
Visit ID : OP017155  
Report Date : 10-06-2019 15:17

## X-Ray

### X-RAY CHEST PA VIEW

*Mid expiratory radiograph.*

Bilateral lung fields appears are grossly normal. No obvious pulmonary parenchymal lesion is seen.


Trachea is central.

Cardiac configuration appears to be normal with normal cardio-thoracic ratio.

Both costo phrenic angles and domes of diaphragm are normal.

Visualized soft tissue and bony thoracic cage appears to be normal.

PLEASE CORRELATE CLINICALLY.



DR. PAWAN JOON  
MD (Radio-diagnosis)

## VIVEKANAND AROGYA KENDRA

<b>Patient Details</b>	Date: 10-Jun-19	Time: 12:44:49 PM
Name: PRAVEEN RATHOR ID: MR008176		
Age: 33 y	Sex: MR	Height: 163 cms.
Clinical History: NOTHING SIGNIFICANT		Weight: 68 Kg.

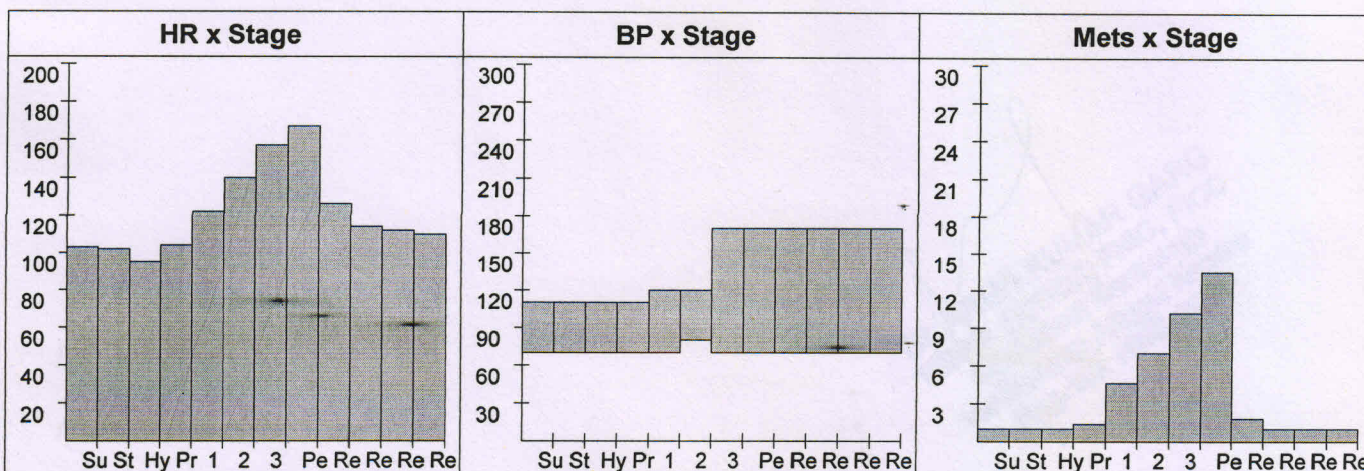
**Medications:** NIL

### Test Details

<b>Protocol:</b> Bruce	<b>Pr.MHR:</b> 187 bpm	<b>THR:</b> 168 (90 % of Pr.MHR) bpm
<b>Total Exec. Time:</b> 9 m 34 s	<b>Max. HR:</b> 167 ( 89% of Pr.MHR )bpm	<b>Max. Mets:</b> 13.50
<b>Max. BP:</b> 170 / 70 mmHg	<b>Max. BP x HR:</b> 28390 mmHg/min	<b>Min. BP x HR:</b> 6650 mmHg/min
<b>Test Termination Criteria:</b> THR achieved		

### Protocol Details

Stage Name	Stage Time (min : sec)	Mets	Speed (mph)	Grade (%)	Heart Rate (bpm)	Max. BP (mm/Hg)	Max. ST Level (mm)	Max. ST Slope (mV/s)
Supine	0 : 19	1.0	0	0	103	110 / 70	-1.06 aVR	1.42 II
Standing	0 : 19	1.0	0	0	102	110 / 70	-1.06 aVR	1.77 II
Hyperventilation	0 : 17	1.0	0	0	95	110 / 70	-0.85 aVR	1.42 II
1	3 : 0	4.6	1.7	10	122	120 / 70	-0.85 aVR	2.12 II
2	3 : 0	7.0	2.5	12	140	120 / 80	-1.70 aVR	3.18 II
3	3 : 0	10.2	3.4	14	157	170 / 70	-1.70 III	3.54 II
Peak Ex	0 : 34	13.5	4.2	16	167	170 / 70	-1.91 aVR	5.66 II
Recovery(1)	1 : 0	1.8	1	0	126	170 / 70	-1.91 aVR	5.66 V4
Recovery(2)	1 : 0	1.0	0	0	114	170 / 70	-1.91 aVR	5.31 V4
Recovery(3)	1 : 0	1.0	0	0	112	170 / 70	-1.06 aVR	3.54 II
Recovery(4)	0 : 5	1.0	0	0	110	170 / 70	-0.85 aVR	2.12 II



# VIVEKANAND AROGYA KENDRA


**Patient Details**      **Date:** 10-Jun-19      **Time:** -12:44:49 PM  
**Name:** PRAVEEN RATHOR **ID:** MR008176  
**Age:** 33 y      **Sex:** MR      **Height:** 163 cms      **Weight:** 68 Kgs

## Interpretation

No significant ST-T changes and no significant symptoms seen during stress TMT.  
TMT is negative for stress induced myocardial ischemia.  
Please correlate clinically.

Ref. Doctor: -----

( Summary Report edited by user )

  
**Dr. ARUN KUMAR GARG**  
**MBBS, PGDCC, FNIC, FICC**  
**Consultant Cardiology**  
**Vivekanand Arogya Kendra**  
**Reg. No: IMC-9027**

Doctor: -----