

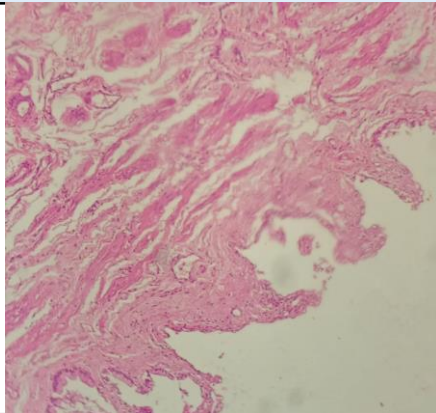
Patient Name	Mrs. ZYTOONA 542	Client Name	Apollo Laboratories CC,	Specimen Received	17/06/2019
MACHIL			Jammu & Kashmir	Specimen Type	Tissue
Age/Sex	65 Years/Female	Ordering Physician	PROF G M SHEIKH MS	Collection Date	17/06/2019
Patient ID	011906170018			Report Date	21/06/2019
Specimen ID	MOLQ/B-1136/19				

SURGICAL PATHOLOGY REPORT

Gall bladder

DIAGNOSIS

CHOLECYSTITIS WITH CHOLELITHIASIS



SPECIMEN

Gall bladder

GROSS

Received 6.5x3.1cm long gall bladder cut section shows stones.

Microscopy

Section examined shows ulcerative mucosa and Rokitansky-Aschoff sinuses (irregularly shaped tubular structures lined by cuboidal lining epithelium with round to oval nucleus) with fibro collagenous tissue and inflammatory cells (lymphocytes).

Note : All biopsy specimen will be stored for 15 (fifteen)days, block and slides for 5(five) years only from the time of receipt at the laboratory. No request ,for any of the above ,will be entertained after the due date.

Reference

- i) Rosai and Ackerman's Surgical Pathology.
- ii) Modern Surgical Pathology.

Gulshan Yadav, MD
Consultant Pathologist