

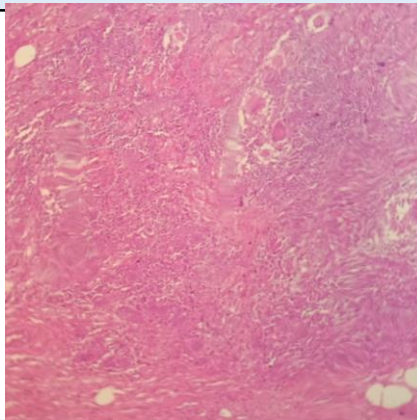
<b>Patient Name</b>	<b>Ms. SAJEEDA</b>	<b>Client Name</b>	Kanwar Clinical Lab,(Hathin)	<b>Specimen Received</b>	15/06/2019
<b>Age/Sex</b>	45 Years/Female			<b>Specimen Type</b>	Tissue
<b>Patient ID</b>	011906150257			<b>Collection Date</b>	15/06/2019
<b>Specimen ID</b>	MOLQ/B-1130/19			<b>Report Date</b>	21/06/2019

## SURGICAL PATHOLOGY REPORT

### Left breast

#### DIAGNOSIS

**Granulomatous reaction.**



#### SPECIMEN

Left breast

#### GROSS

Received multiple greyish white tissue piece 6x5cm in aggregate.

#### Microscopy

Section examined shows epithelioid cells in granuloma surrounding by lymphocytes and multinucleated giant cells.

Section also shows fibro collagenous tissue, blood vessels and ducts.

**Note :** All biopsy specimen will be stored for 15 (fifteen)days, block and slides for 5(five) years only from the time of receipt at the laboratory. No request ,for any of the above ,will be entertained after the due date.

#### Reference

- i) Rosai and Ackerman's Surgical Pathology.
- ii) Modern Surgical Pathology.

**Gulshan Yadav, MD**  
**Consultant Pathologist**