

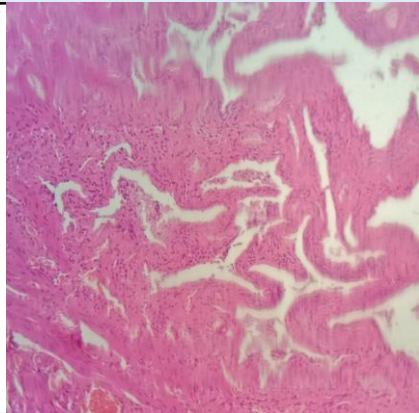
<b>Patient Name</b>	<b>Mr. MUZAFER AH 9390</b>	<b>Client Name</b>	Patients Care Clinical	<b>Specimen Received</b>	15/06/2019
<b>Age/Sex</b>	13 Years/Male		Laboratory, Jammu & Kashmir	<b>Specimen Type</b>	Tissue
<b>Patient ID</b>	011906150039			<b>Collection Date</b>	15/06/2019
<b>Specimen ID</b>	MOLQ/B-1126/19			<b>Report Date</b>	21/06/2019

## SURGICAL PATHOLOGY REPORT

### Gall bladder

#### DIAGNOSIS

**CHOLECYSTITIS**



#### SPECIMEN

Gall bladder

#### GROSS

Received autolyzed 6.5x2.8cm long gall bladder already cut open no stones.

#### Microscopy

Section examined shows autolyzed ulcerative mucosa and Rokitansky-Aschoff sinus (irregularly shaped tubular structures lined by cuboidal lining epithelium with round to oval nucleus) with fibro collagenous tissue and inflammatory cells (lymphocytes).

**Note :** All biopsy specimen will be stored for 15 (fifteen) days, block and slides for 5 (five) years only from the time of receipt at the laboratory. No request, for any of the above, will be entertained after the due date.

#### Reference

- i) Rosai and Ackerman's Surgical Pathology.
- ii) Modern Surgical Pathology.

**Gulshan Yadav, MD**  
Consultant Pathologist