

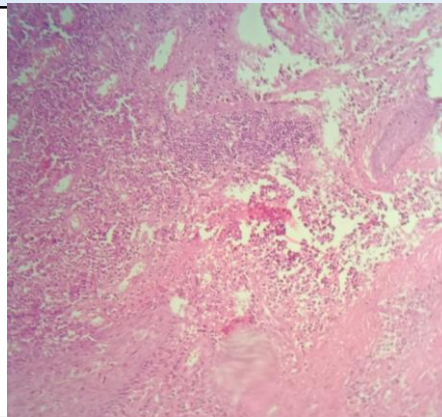
| | | | | | |
|---------------------|----------------------------|--------------------|-------------------------|--------------------------|------------|
| Patient Name | Mr. NETAR PAL SINGH | Client Name | Uttam Diagnostics, Agra | Specimen Received | 15/06/2019 |
| Age/Sex | 36 Years/Male | | | Specimen Type | Tissue |
| Patient ID | 011906150006 | | | Collection Date | 15/06/2019 |
| Specimen ID | MOLQ/B-1125/19 | | | Report Date | 21/06/2019 |

SURGICAL PATHOLOGY REPORT

Hip cyst

DIAGNOSIS

Acute on Chronic Infective lesion with Granulation tissue.



SPECIMEN

Hip cyst

GROSS

Received two greyish white tissue piece measuring 6x3,4x2.5cm with skin and opening .

Microscopy

Section examined shows squamous lining epithelium with hyperkeratosis. Dermis shows fibro collagenous tissue, glands with large number of blood vessels.

Section also shows large number of inflammatory cells (polymorphs, lymphocytes, histiocytes) and multinucleated giant cells.

Note : All biopsy specimen will be stored for 15 (fifteen)days, block and slides for 5(five) years only from the time of receipt at the laboratory. No request ,for any of the above ,will be entertained after the due date.

Reference

- i) Rosai and Ackerman's Surgical Pathology.
- ii) Modern Surgical Pathology.

Gulshan Yadav, MD
Consultant Pathologist