


Mukesh
Bachkhedi



BA Continuum India Pvt. Ltd.
A nonbank subsidiary of Bank of America Corporation

 भारत सरकार
GOVERNMENT OF INDIA



Mukesh Chandra Bachkhedi
DOB: 30/06/1990
Male / MALE



9223 7115 3892
Aadhaar-Aam Aadmi ka Adhikar

CERTIFICATE OF MEDICAL FITNESS

This is to certify that I have conducted the clinical examination

of Mukesh Baulkheti on _____


After reviewing the medical history and on clinical examination it has been found that he/she is

	Tick
<ul style="list-style-type: none"> • Medically Fit 	<input type="checkbox"/>
<ul style="list-style-type: none"> • Fit with restrictions/recommendations <p>Though following restrictions have been revealed, in my opinion, these are not impediments to the job.</p> <p>1. <u>Mild dyslipidemia</u></p> <p>2.</p> <p>3.</p> <p>However the employee should follow the advice/medication that has been communicated to him/her.</p> <p>Review after <u>6m.</u></p>	<input type="checkbox"/>
<ul style="list-style-type: none"> • Currently Unfit. <p>Review after _____ recommended</p>	<input type="checkbox"/>
<ul style="list-style-type: none"> • Unfit 	<input type="checkbox"/>

Dr. Aug 0

Medical Officer
 The Apollo Clinic, (Location)
 Consulting Physician
 MBBS, MD
 Regd. No. 7513 (HMC)

This certificate is not meant for medico-legal purposes


Dr. ASHOK K. GUPTA
MBBS, MD
Consulting Physician
Regd. No. 7513 (HMC)

उपलब्ध ओ.पी.डी. सुविधाएँ

- हृदय रोग चिकित्सा
(Cardiology)
- बाल एवं भ्रूण रोग चिकित्सा
(Paediatrics & Fetal Medicine)
- बाल रोग चिकित्सा
(Paediatrics)
- स्त्री रोग चिकित्सा
(Gynaecology)
- हड्डी रोग चिकित्सा
(Orthopaedics)
- दन्त चिकित्सा
(Dental Care)
- सामान्य चिकित्सा
(General Physician)
- फिजियोथैरेपी
(Physiotherapy)
- चर्म रोग चिकित्सा
(Dermatology)
- मूत्र रोग चिकित्सा
(Urology)
- गुर्दा रोग चिकित्सा
(Nephrology)

उपलब्ध जाँच

- डायलिसिस (Dialysis)
- अल्ट्रासाउण्ड (Ultrasound)
- ईको (Echo)
- स्ट्रेस ईको (Stress Echo)
- टी.एम.टी. (T.M.T.)
- पी.एफ.टी. (Lung Function Test)
- ई.सी.जी. (E.C.G.)
- ई.ई.जी. (E.E.G.)
- एक्स-रे (X-Ray)
- मैमोग्राफी (Mammography)
- ओ.पी.जी. (Dental X-Ray)
- हॉल्टर टेस्ट (Holter Test)

Ref. No.:.....

Date:.....

Name of patient: Mr. Mukesh Bachkhe	Age: 29	M/F: M
Consultant:	Speciality: Package	
MR No : MR008452	Visit No: OP017773	Date: 15-06-2019

HT 5'9"
WL 87.5 kg
PR 66bpm
BP 110/70 mmHg
Chesty
CNS
Med

Not for Medico Legal Purpose

रूख एवं मल-मूत्र की जाँच NABL द्वारा मान्यता प्राप्त MoIQ लैब द्वारा की जाती है।

सम्पर्क सूत्र: 0124-2224102 / 103 / 104 | Mob.: 8683061905, 8683061906

ओ.पी.डी. पर्ची का शुल्क केवल तीन दिन के लिए मान्य रहेगा।

Radiology Report

Name : Mr. Mukesh Bachkheti
Age/Gender : 29 Y/M
Prescribed Doctor : Self

MR No : MR008452
Visit ID : OP017773
Report Date : 15-06-2019 15:31

Ultrasound

USG EXAMINATION : WHOLE ABDOMEN

Liver shows normal shape and size with homogenous echo texture. Intrahepatic biliary radicals are not dilated. No focal lesion is seen. **Portal Vein** shows normal calibre.

Gall bladder is partially distended. No obvious calculus or mass is seen in the lumen.

CBD is normal in diameter. No calculus is seen

Pancreas is normal in size, shape and echo texture.

Spleen is normal in shape, size and echo texture.

Right kidney show normal shape & size. Cortico-medullary differentiation is maintained. Right kidney show no calculus or hydronephrosis.

Left kidney show normal shape & size. Cortico-medullary differentiation is maintained. Left kidney show no calculus or hydronephrosis.


No free fluid is seen in the intra-peritoneal cavity. No evidence of mesenteric lymphadenopathy is seen.

Urinary bladder is normal in shape, size and wall thickness. No mass or calculus is seen.

Prostate is normal in shape, size & echo texture. Volume of prostate is 12.8cc.

IMP: Normal study.

PLEASE CORRELATE CLINICALLY.


Dr. Pawan Joon
MD (Radio- diagnosis)

Radiology Report

Name : Mr. Mukesh Bachkheti
Age/Gender : 29 Y/M
Prescribed Doctor : Self

MR No : MR008452
Visit ID : OP017773
Report Date : 15-06-2019 16:48

X-Ray

X-RAY CHEST PA VIEW

Bilateral lungs fields are appears to be grossly normal.

Trachea is central.

Both costo phrenic angles and domes of diaphragm are normal.

Cardiac shadows can not be commented upon due to expiratory radiograph.

Soft tissue and bony thoracic cage are normal.

PLEASE CORRELATE CLINICALLY.


DR.PAWAN JOON
MD (Radio-diagnosis)

VIVEKANAND AROGYA KENDRA

Patient Details	Date: 15-Jun-19	Time: 4:09:32 PM
Name: Mukesh Bachkhe ID: Mr008452		
Age: 29 y	Sex: M	Height: 58 cms
Weight: 87 Kgs		
Clinical History: nothing significant		

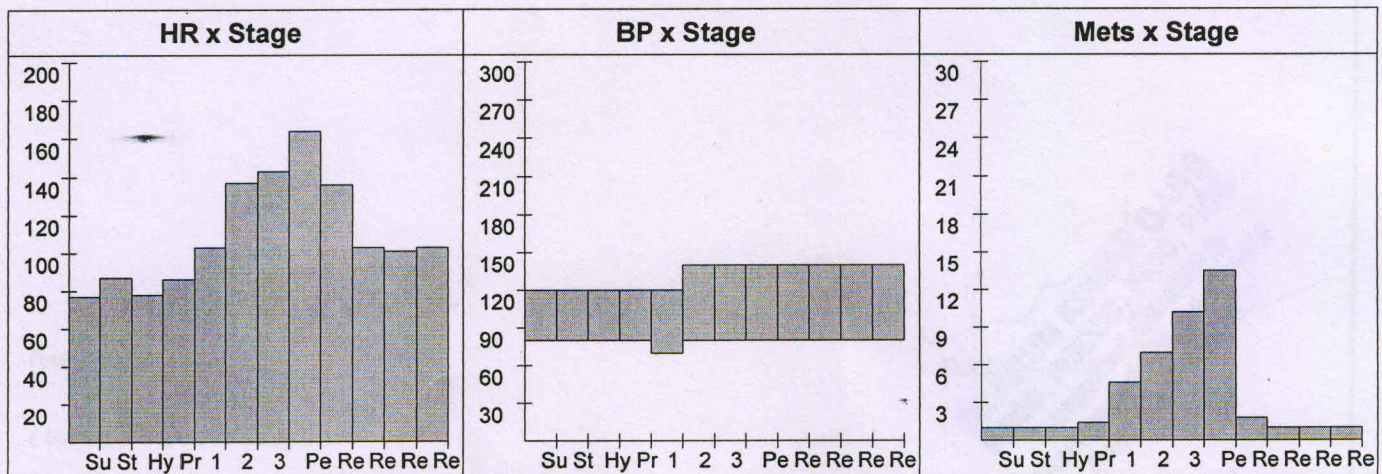
Medications: nil

Test Details

Protocol: Bruce	Pr.MHR: 191 bpm	THR: 162 (85 % of Pr.MHR) bpm
Total Exec. Time: 10 m 41 s	Max. HR: 164 (86% of Pr.MHR) bpm	Max. Mets: 13.50
Max. BP: 140 / 80 mmHg	Max. BP x HR: 22960 mmHg/min	Min. BP x HR: 5390 mmHg/min
Test Termination Criteria: THR achieved		

Protocol Details

Stage Name	Stage Time (min : sec)	Mets	Speed (mph)	Grade (%)	Heart Rate (bpm)	Max. BP (mm/Hg)	Max. ST Level (mm)	Max. ST Slope (mV/s)
Supine	0 : 23	1.0	0	0	77	120 / 80	-1.06 aVR	1.42 V2
Standing	0 : 29	1.0	0	0	87	120 / 80	-1.27 aVR	1.42 II
Hyperventilation	0 : 11	1.0	0	0	78	120 / 80	-1.27 aVR	1.42 II
1	3 : 0	4.6	1.7	10	103	120 / 70	-1.49 aVR	2.12 II
2	3 : 0	7.0	2.5	12	137	140 / 80	-1.49 aVR	2.83 II
3	3 : 0	10.2	3.4	14	143	140 / 80	-1.49 III	3.54 I
Peak Ex	1 : 41	13.5	4.2	16	164	140 / 80	-1.49 III	3.54 II
Recovery(1)	1 : 0	1.8	1	0	136	140 / 80	-2.34 aVR	4.60 II
Recovery(2)	1 : 0	1.0	0	0	103	140 / 80	-2.34 aVR	4.60 II
Recovery(3)	1 : 0	1.0	0	0	101	140 / 80	-1.49 aVR	3.18 II
Recovery(4)	0 : 28	1.0	0	0	103	140 / 80	-1.27 aVR	2.48 II



VIVEKANAND AROGYA KENDRA

Patient Details

Date: 15-Jun-19

Time: 4:09:32 PM

Name: Mukesh Bachkhe ID: Mr008452

Age: 29 y

Sex: M

Height: 58 cms

Weight: 87 Kgs

Interpretation

No significant ST-T changes seen during TMT.
TMT is negative for stress induced myocardial ischemia seen.
Please correlate clinically.

Ref. Doctor: -----

(Summary Report edited by user)

Doctor: -----

Dr. ALUN KUMAR GARG
MBBS, FRCPC, FNIC, FICG, FICG
Consultant Cardiologist
Vivekanand Arogya Kendra
Reg. No. MMC-8027