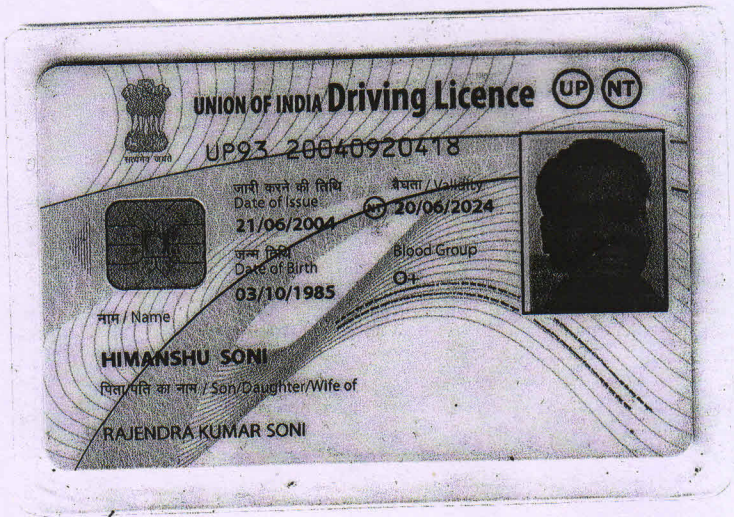


CERTIFICATE OF MEDICAL FITNESS

This is to certify that I have conducted the clinical examination

of Himanshu Soui on _____

After reviewing the medical history and on clinical examination it has been found that he/she is

	Tick
<ul style="list-style-type: none"> • Medically Fit 	<input type="checkbox"/>
<ul style="list-style-type: none"> • Fit with restrictions/recommendations <p>Though following restrictions have been revealed, in my opinion, these are not impediments to the job.</p> <p>1. <u>Mild dyslipidemic</u>.....</p> <p>2.....</p> <p>3.....</p> <p>However the employee should follow the advice/medication that has been communicated to him/her.</p> <p>Review after <u>6 m</u></p>	<input type="checkbox"/>
<ul style="list-style-type: none"> • Currently Unfit. Review after _____ recommended 	<input type="checkbox"/>
<ul style="list-style-type: none"> • Unfit 	<input type="checkbox"/>

Dr. 
 Medical Officer _____
 The Apollo Clinic, (Location)

DR. ASHOK K. GUPTA
MBBS, MD
Consulting Physician
Regd. No. 7513 (HMC)

This certificate is not meant for medico-legal purposes

उपलब्ध ओ.पी.डी. सुविधाएँ

- हृदय रोग चिकित्सा
(Cardiology)
- बाल एवं भ्रूण रोग चिकित्सा
(Paediatrics & Fetal Medicine)
- बाल रोग चिकित्सा
(Paediatrics)
- स्त्री रोग चिकित्सा
(Gynaecology)
- हड्डी रोग चिकित्सा
(Orthopaedics)
- दन्त चिकित्सा
(Dental Care)
- सामान्य चिकित्सा
(General Physician)
- फिजियोथैरेपी
(Physiotherapy)
- चर्म रोग चिकित्सा
(Dermatology)
- मूत्र रोग चिकित्सा
(Urology)
- गुर्दा रोग चिकित्सा
(Nephrology)

उपलब्ध जाँच

- डायलिसिस (Dialysis)
- अल्ट्रासाउण्ड (Ultrasound)
- ईको (Echo)
- स्ट्रेस ईको (Stress Echo)
- टी.एम.टी. (T.M.T.)
- पी.एफ.टी. (Lung Function Test)
- ई.सी.जी. (E.C.G.)
- ई.ई.जी. (E.E.G.)
- एक्स-रे (X-Ray)
- मैमोग्राफी (Mammography)
- ओ.पी.जी. (Dental X-Ray)
- हॉल्टर टेस्ट (Holter Test)

Ref. No.:.....

Date:.....

Name of patient: Mr. Himanshu Soni	Age: 33	M/F: M
Consultant:	Speciality: Package	
MR No : MR008434	Visit No: OP017732	Date: 15-06-2019

Ht = 5'8"

Wt = 69.5 kg

RA = 278 gmt

Bp = 110/70 mm Hg

Chest
CVS / r
Abd

Not for Medico Legal Purpose

खून एवं मल-मूत्र की जाँच NABL द्वारा मान्यता प्राप्त MolQ लैब द्वारा की जाती है।

सम्पर्क सूत्र: 0124-2224102 / 103 / 104 | Mob.: 8683061905, 8683061906

ओ.पी.डी. पर्ची का शुल्क केवल तीन दिन के लिए मान्य रहेगा।



विवेकानन्द आरोग्य केन्द्र

डायग्नोसिस, डायग्नोस्टिक एवं ओपी.डी.
भारत विकास परिषद्, महाराणा प्रताप न्यास द्वारा संचालित



Radiology Report

Name : Mr. Himanshu Soni
Age/Gender : 33 Y/M
Prescribed Doctor : Self

MR No : MR008434
Visit ID : OP017732
Report Date : 15-06-2019 11:46

Ultrasound


USG EXAMINATION : WHOLE ABDOMEN

Liver shows normal shape and size with homogenous echo texture. Intrahepatic biliary radicals are not dilated. No focal lesion is seen. **Portal Vein** shows normal calibre.
Gall bladder shows physiological distension and normal wall thickness. No calculus or mass is seen in the lumen.
CBD is normal in diameter. No calculus is seen
Pancreas is normal in size, shape and echo texture.
Spleen is normal in shape, size and echo texture.

Right kidney show normal shape & size. Cortico-medullary differentiation is maintained. Right kidney show no calculus or hydronephrosis.
Left kidney show normal shape & size. Cortico-medullary differentiation is maintained. Left kidney show no calculus or hydronephrosis.
No free fluid is seen in the intra-peritoneal cavity. No evidence of mesenteric lymphadenopathy is seen.
Urinary bladder is normal in shape, size and wall thickness. No mass or calculus is seen.
Prostate is normal in shape, size & echo texture.

IMP: Normal study.

PLEASE CORRELATE CLINICALLY.


Dr. Pawan Joon
MD (Radio- diagnosis)

Radiology Report

Name : Mr. Himanshu Soni
Age/Gender : 33 Y/M
Prescribed Doctor : Self

MR No : MR008434
Visit ID : OP017732
Report Date : 15-06-2019 16:41

X-Ray

X-RAY CHEST PA VIEW

Bilateral lungs fields are appears to be grossly normal.

Trachea is central.

Both costo phrenic angles and domes of diaphragm are normal.

Cardiac shadows can not be commented upon due to expiratory radiograph.

Soft tissue and bony thoracic cage are normal.

PLEASE CORRELATE CLINICALLY.


DR.PAWAN JOON
MD (Radio-diagnosis)

VIVEKANAND AROGYA KENDRA

Patient Details **Date:** 15-Jun-19 **Time:** 2:07:57 PM
Name: HIMANSHU SONI ID: MR008434
Age: 33 y **Sex:** M **Height:** 58 cms **Weight:** 69 Kgs
Clinical History: NOTHING SIGNIFICANT

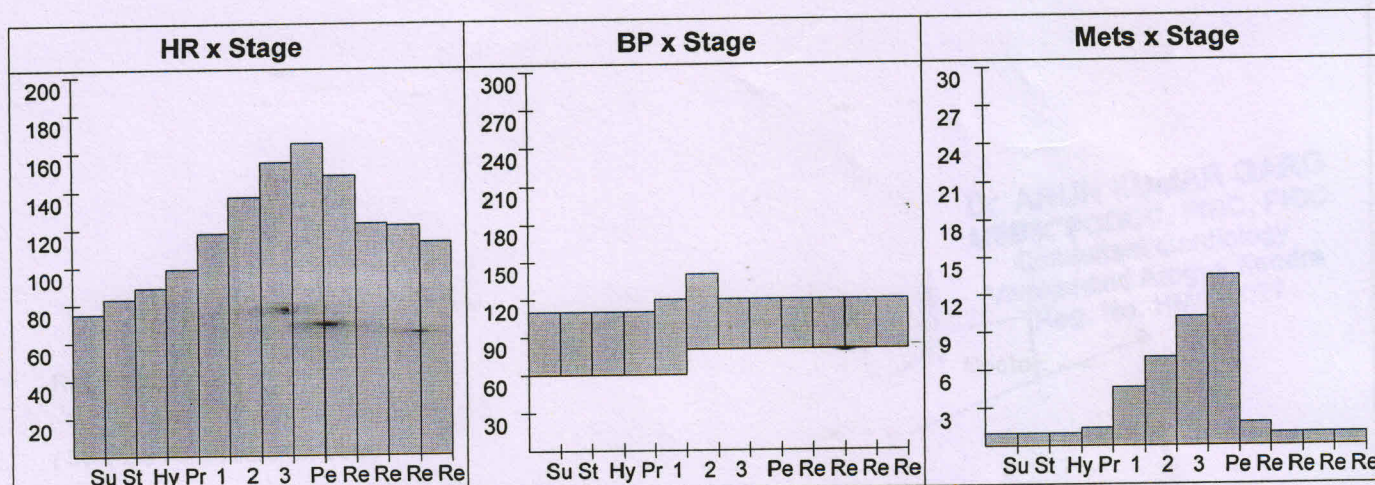
Medications: NIL

Test Details

Protocol: Bruce **Pr.MHR:** 187 bpm **THR:** 158 (85 % of Pr.MHR) bpm
Total Exec. Time: 9 m 31 s **Max. HR:** 165 (88% of Pr.MHR)bpm **Max. Mets:** 13.50
Max. BP: 140 / 80 mmHg **Max. BP x HR:** 23100 mmHg/min **Min. BP x HR:** 4500 mmHg/min
Test Termination Criteria: THR achieved

Protocol Details

Stage Name	Stage Time (min : sec)	Mets	Speed (mph)	Grade (%)	Heart Rate (bpm)	Max. BP (mm/Hg)	Max. ST Level (mm)	Max. ST Slope (mV/s)
Supine	0 : 16	1.0	0	0	75	110 / 60	-0.85 aVR	1.42 V3
Standing	0 : 23	1.0	0	0	83	110 / 60	-0.85 aVR	1.42 V3
Hyperventilation	0 : 15	1.0	0	0	89	110 / 60	-0.85 aVR	1.06 V4
1	3 : 0	4.6	1.7	10	118	120 / 60	-1.27 aVR	2.48 V5
2	3 : 0	7.0	2.5	12	137	140 / 80	-1.27 aVR	5.66 V5
3	3 : 0	10.2	3.4	14	155	120 / 80	-1.49 aVR	5.31 V4
Peak Ex	0 : 31	13.5	4.2	16	165	120 / 80	-1.06 aVR	4.95 V4
Recovery(1)	1 : 0	1.8	1	0	148	120 / 80	-2.12 aVR	5.66 V3
Recovery(2)	1 : 0	1.0	0	0	123	120 / 80	-1.91 aVR	5.66 V4
Recovery(3)	1 : 0	1.0	0	0	122	120 / 80	-1.27 aVR	3.18 V4
Recovery(4)	0 : 14	1.0	0	0	113	120 / 80	-0.85 aVR	1.77 II



VIVEKANAND AROGYA KENDRA

Patient Details

Date: 15-Jun-19

Time: 2:07:57 PM

Name: HIMANSHU SONI ID: MR008434

Age: 33 y

Sex: M

Height: 58 cms


Weight: 69 Kgs

Interpretation

No significant ST-T changes seen during TMT.
TMT is negative for stress induced myocardial ischemia seen.
Please correlate clinically.

Dr. ARUN KUMAR GARG
MBBS, PGDCC, FNIC, FICC
Consultant Cardiology
Vivekanand Arogya Kendra
Reg. No. HMC-8027

Ref. Doctor: -----


Doctor: -----

(Summary Report edited by user)