

Mudit Chawla



BA Continuum India Pvt. Ltd.
A member company of The Chartered Accountants


भारत सरकार
GOVT OF INDIA

भारत सरकार
MUDIT CHAWLA


भारत सरकार
SURENDRA LAL CHAWLA

05/07/1978

Permanent Account Number
AENPC3906Q



Signature



18082010


CERTIFICATE OF MEDICAL FITNESS

This is to certify that I have conducted the clinical examination

of Mudit Chawla on _____

After reviewing the medical history and on clinical examination it has been found that he/she is

	Tick
<ul style="list-style-type: none"> • Medically Fit 	<input type="checkbox"/>
<ul style="list-style-type: none"> • Fit with restrictions/recommendations <p>Though following restrictions have been revealed, in my opinion, these are not impediments to the job.</p> <p>1. <u>Dyslipidemic</u>.....</p> <p>2.....</p> <p>3.....</p> <p>However the employee should follow the advice/medication that has been communicated to him/her.</p> <p>Review after <u>6 m</u></p>	<input type="checkbox"/>
<ul style="list-style-type: none"> • Currently Unfit. Review after _____ recommended 	<input type="checkbox"/>
<ul style="list-style-type: none"> • Unfit 	<input type="checkbox"/>

Dr. 
Medical Officer
 The Apollo Clinic, (Location)

Dr. ASHOK K. GUPTA
MBBS, MD
Consulting Physician
Regd. No. 7513 (HMC)

This certificate is not meant for medico-legal purposes

उपलब्ध ओ.पी.डी. सुविधाएँ

- हृदय रोग चिकित्सा
(Cardiology)
- बाल एवं भ्रूण रोग चिकित्सा
(Paediatrics & Fetal Medicine)
- बाल रोग चिकित्सा
(Paediatrics)
- स्त्री रोग चिकित्सा
(Gynaecology)
- हड्डी रोग चिकित्सा
(Orthopaedics)
- दन्त चिकित्सा
(Dental Care)
- सामान्य चिकित्सा
(General Physician)
- फिजियोथैरेपी
(Physiotherapy)
- चर्म रोग चिकित्सा
(Dermatology)
- मूत्र रोग चिकित्सा
(Urology)
- गुर्दा रोग चिकित्सा
(Nephrology)

उपलब्ध जाँच

- डायलिसिस (Dialysis)
- अल्ट्रासाउण्ड (Ultrasound)
- ईको (Echo)
- स्ट्रेस ईको (Stress Echo)
- टी.एम.टी. (T.M.T.)
- पी.एफ.टी. (Lung Function Test)
- ई.सी.जी. (E.C.G.)
- ई.ई.जी. (E.E.G.)
- एक्स-रे (X-Ray)
- मैमोग्राफी (Mammography)
- ओ.पी.जी. (Dental X-Ray)
- हॉल्टर टेस्ट (Holter Test)

Ref. No.:.....

Date:.....

Name of patient: Mr. Mudit Chawla	Age: 40	M/F: M
Consultant:	Speciality: Package	
MR No : MR008425	Visit No: OP017713	Date: 15-06-2019

HT - 5'8"
WT - 80.9 kg
Hb - 7.8 gm/dl
BP - 120/76 mmHg
Chest |
CVS |
Abd |

Not for Medico Legal Purpose

खून एवं मल-मूत्र की जाँच NABL द्वारा मान्यता प्राप्त MoIQ लैब द्वारा की जाती है।

सम्पर्क सूत्र: 0124-2224102 / 103 / 104 | Mob.: 8683061905, 8683061906

ओ.पी.डी. पर्ची का शुल्क केवल तीन दिन के लिए मान्य रहेगा।

Radiology Report

Name : Mr. Mudit Chawla

MR No : MR008425

Age/Gender : 40 Y/M

Visit ID : OP017713

Prescribed Doctor : Self

Report Date : 15-06-2019 11:48

Ultrasound

USG EXAMINATION : WHOLE ABDOMEN

Liver shows normal shape and size with homogenous echo texture. Intrahepatic biliary radicals are not dilated. No focal lesion is seen. **Portal Vein** shows normal calibre.

Gall bladder shows physiological distension and normal wall thickness. No calculus or mass is seen in the lumen.

CBD is normal in diameter. No calculus is seen

Pancreas is normal in size, shape and echo texture.

Spleen is normal in shape, size and echo texture.

Right kidney show normal shape & size. Cortico-medullary differentiation is maintained. Right kidney show no calculus or hydronephrosis.

Left kidney show normal shape & size. Cortico-medullary differentiation is maintained. Left kidney show no calculus or hydronephrosis.


No free fluid is seen in the intra-peritoneal cavity. No evidence of mesenteric lymphadenopathy is seen.

Urinary bladder is normal in shape, size and wall thickness. No mass or calculus is seen.

Prostate is normal in shape, size & echo texture. Volume of prostate is 14.5cc.

IMP: Normal study.

PLEASE CORRELATE CLINICALLY.


Dr. Pawan Joon
MD (Radio- diagnosis)

Radiology Report

Name : Mr. Mudit Chawla
Age/Gender : 40 Y/M
Prescribed Doctor : Self

MR No : MR008425
Visit ID : OP017713
Report Date : 15-06-2019 16:40

X-Ray

X-RAY CHEST PA VIEW

Bilateral lungs fields are appears to be grossly normal.


Trachea is central.

Both costo phrenic angles and domes of diaphragm are normal.

Cardiac shadows can not be commented upon due to expiratory radiograph.

Soft tissue and bony thoracic cage are normal.

PLEASE CORRELATE CLINICALLY.


DR.PAWAN JOON
MD (Radio-diagnosis)

VIVEKANAND AROGYA KENDRA

Patient Details Date: 15-Jun-19 Time: 12:07:11 PM
Name: MUDIT CHAWLA ID: MR008425 Height: 170 cms. Weight: 80 Kg.
Age: 40 y Sex: M
Clinical History: nothing significant

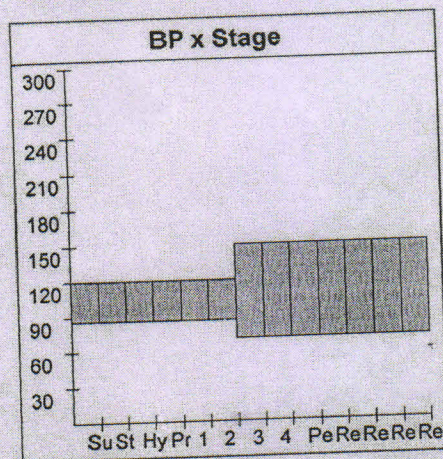
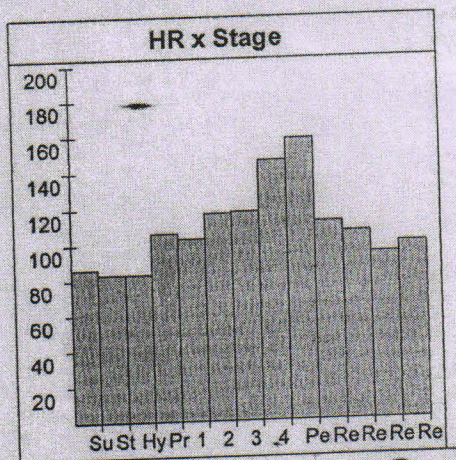
Medications: nil

Test Details

Protocol: Bruce **Pr.MHR:** 180 bpm **THR:** 153 (85 % of Pr.MHR) bpm
Total Exec. Time: 12 m 16 s **Max. HR:** 158 (88 % of Pr.MHR) bpm **Max. Mets:** 17.23
Max. BP: 150 / 70 mmHg **Max. BP x HR:** 23700 mmHg/min **Min. BP x HR:** 5810 mmHg/min
Test Termination Criteria: THR achieved

Protocol Details

Stage Name	Stage Time (min : sec)	Speed (mph)	Grade (%)	Heart Rate (bpm)	Max. BP (mm/Hg)	Max. ST Level (mm)	Max. ST Slope (mV/s)
Supine	0 : 16	0	0	86	120 / 86	-0.64 aVR	1.06 II
Standing	0 : 27	0	0	83	120 / 86	-0.64 aVR	1.06 II
Hyperventilation	0 : 11	0	0	83	120 / 86	-0.64 aVR	1.06 II
1	3 : 0	1.7	10	103	120 / 86	-0.42 III	1.06 II
2	3 : 0	2.5	12	117	120 / 86	-1.06 V1	2.12 II
3	3 : 0	3.4	14	118	150 / 70	-3.40 V2	3.89 II
4	3 : 0	4.2	16	146	150 / 70	-2.12 V1	3.18 II
Peak Ex	0 : 16	5	18	158	150 / 70	-1.27 III	3.18 V4
Recovery(1)	1 : 0	1	0	112	150 / 70	-1.27 III	4.25 II
Recovery(2)	1 : 0	0	0	106	150 / 70	-0.85 aVR	3.18 II
Recovery(3)	1 : 0	0	0	94	150 / 70	-0.21 aVR	1.77 II
Recovery(4)	0 : 10	0	0	100	150 / 70	-0.21 aVR	1.42 aVF



VIVEKANAND AROGYA KENDRA

Patient Details

Date: 15-Jun-19

Time: 12:07:11 PM

Name: MUDIT CHAWLA ID: MR008425

Age: 40y

Sex: M

Height: 170 cms.

Weight: 80 Kg.

Interpretation

No significant ST-T changes seen during stress testing.
TMT is negative for stress induced myocardial ischemia.
Please correlate clinically.

Ref. Doctor: -----

Doctor:  -----*(Summary Report edited by user)*