

Nikhil Kumar
Choudhary



BA Continuum India Pvt. Ltd.
A nonbank subsidiary of Bank of America Corporation




सत्यमेव जयते

भारत सरकार



निखिल कुमार चौधरी
Nikhil Kumar Choudhary
जन्म तिथि/ DOB: 30/11/1989
पुरुष / MALE



3906 0279 5982

आधार-आम आदमी का अधिकार

CERTIFICATE OF MEDICAL FITNESS

This is to certify that I have conducted the clinical examination

of Nikhil Chaudhary on _____

After reviewing the medical history and on clinical examination it has been found that he/she is

	Tick
<ul style="list-style-type: none"> • Medically Fit 	<input type="checkbox"/>
<ul style="list-style-type: none"> • Fit with restrictions/recommendations <p>Though following restrictions have been revealed, in my opinion, these are not impediments to the job.</p> <p>1.....<u>Dyslipidemia</u>.....</p> <p>2.....<u>Mild increase in Transaminases</u>.....</p> <p>3.....</p> <p>However the employee should follow the advice/medication that has been communicated to him/her.</p> <p>Review after <u>1 m</u></p>	<input type="checkbox"/>
<ul style="list-style-type: none"> • Currently Unfit. Review after _____ recommended 	<input type="checkbox"/>
<ul style="list-style-type: none"> • Unfit 	<input type="checkbox"/>

Dr. Anil
 Medical Officer
 The Apollo Clinic (Location)

DR. ASHOK GUPTA
 MBBS, MD
 Consulting Physician
 Regd. No. 7513 (HMC)

This certificate is not meant for medico-legal purposes

उपलब्ध ओ.पी.डी. सुविधाएँ

- हृदय रोग चिकित्सा
(Cardiology)
- बाल एवं भ्रूण रोग चिकित्सा
(Paediatrics & Fetal Medicine)
- बाल रोग चिकित्सा
(Paediatrics)
- स्त्री रोग चिकित्सा
(Gynaecology)
- हड्डी रोग चिकित्सा
(Orthopaedics)
- दन्त चिकित्सा
(Dental Care)
- सामान्य चिकित्सा
(General Physician)
- फिजियोथैरेपी
(Physiotherapy)
- चर्म रोग चिकित्सा
(Dermatology)
- मूत्र रोग चिकित्सा
(Urology)
- गुर्दा रोग चिकित्सा
(Nephrology)

Ref. No.:.....

Date:.....

Name of patient: Mr. Nikhil Chaudhary	Age: 29	M/F: M
Consultant:	Speciality: Package	
MR No : MR008454	Visit No: OP017777	Date: 15-06-2019

HT 5'11"

WT 82.9 kg

BP 100/70 mmHg

HR 140/96 mmHg

Chest 2

Clear

CVS / 6

उपलब्ध जाँच

- डायलिसिस (Dialysis)
- अल्ट्रासाउण्ड (Ultrasound)
- ईको (Echo)
- स्ट्रेस ईको (Stress Echo)
- टी.एम.टी. (T.M.T.)
- पी.एफ.टी. (Lung Function Test)
- ई.सी.जी. (E.C.G.)
- ई.ई.जी. (E.E.G.)
- एक्स-रे (X-Ray)
- मैमोग्राफी (Mammography)
- ओ.पी.जी. (Dental X-Ray)
- हॉल्टर टेस्ट (Holter Test)

Not for Medico Legal Purpose

रून एवं मल-मूत्र की जाँच NABL द्वारा मान्यता प्राप्त MoIQ लैब द्वारा की जाती है।

सम्पर्क सूत्र: 0124-2224102 / 103 / 104 | Mob.: 8683061905, 8683061906

ओ.पी.डी. पर्ची का शुल्क केवल तीन दिन के लिए मान्य रहेगा।



विवेकानन्द आरोग्य केन्द्र

डायग्नोस्टिक एवं ओ.पी.डी.
भारत विकास परिषद्, महाराणा प्रताप न्यास द्वारा संचालित



Radiology Report

Name : Mr. Nikhil Chaudhary
Age/Gender : 29 Y/M
Prescribed Doctor : Self

MR No : MR008454
Visit ID : OP017777
Report Date : 15-06-2019 15:37

Ultrasound

USG EXAMINATION : WHOLE ABDOMEN

Liver shows normal shape and size with homogenous echo texture. Intrahepatic biliary radicals are not dilated. No focal lesion is seen. **Portal Vein** shows normal calibre.

Gall bladder is partially distended. No obvious calculus or mass is seen in the lumen.

CBD is normal in diameter. No calculus is seen

Pancreas is normal in size, shape and echo texture.

Spleen is normal in shape, size and echo texture.

Right kidney show normal shape & size. Cortico-medullary differentiation is maintained. Right kidney show no calculus or hydronephrosis. Right kidney measures 112 x 45mm.

Left kidney show normal shape & size. Cortico-medullary differentiation is maintained. Left kidney show no calculus or hydronephrosis. Left kidney measures 107 x 44mm.


No free fluid is seen in the intra-peritoneal cavity. No evidence of mesenteric lymphadenopathy is seen.

Urinary bladder is normal in shape, size and wall thickness. No mass or calculus is seen.

Prostate is normal in shape, size & echo texture. Volume of prostate is 10cc.

IMP: Normal study.

PLEASE CORRELATE CLINICALLY.


Dr. Pawan Joon
MD (Radio- diagnosis)

Radiology Report

Name : Mr. Nikhil Chaudhary
Age/Gender : 29 Y/M
Prescribed Doctor : Self

MR No : MR008454
Visit ID : OP017777
Report Date : 17-06-2019 12:11

X-Ray

X-RAY CHEST PA VIEW

Rotated & mid expiratory radiograph.

Bilateral lungs fields are appears to be grossly normal.

Trachea is central.

Both costo phrenic angles and domes of diaphragm are normal.

Cardiac shadows can not be commented upon due to expiratory radiograph.

Soft tissue and bony thoracic cage are normal.

PLEASE CORRELATE CLINICALLY.


DR. PAWAN JOON
MD (Radio-diagnosis)

VIVEKANAND AROGYA KENDRA

Patient Details	Date: 15-Jun-19	Time: 4:31:28 PM
Name: NIKHIL CHAUDHARY	ID: MR008454	
Age: 29 y	Sex: M	Height: 244 cms
Clinical History: nothing significant		Weight: 82 Kgs

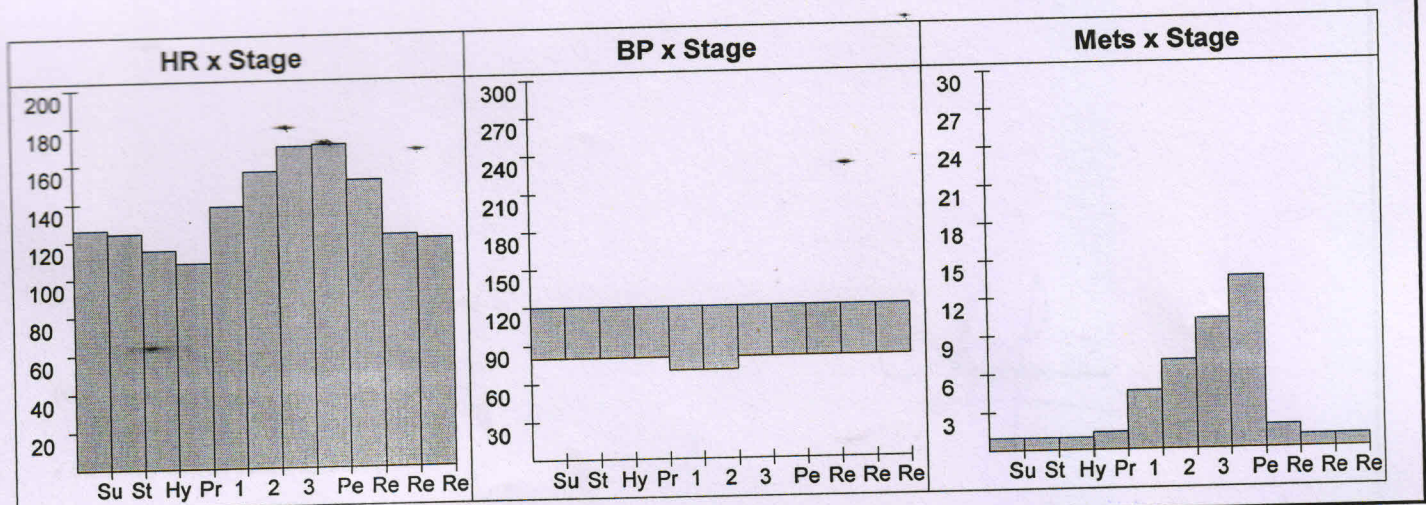
Medications: nil

Test Details

Protocol: Bruce	Pr.MHR: 191 bpm	THR: 162 (85 % of Pr.MHR) bpm
Total Exec. Time: 9 m 5 s	Max. HR: 170 (89% of Pr.MHR) bpm	Max. Mets: 13.50
Max. BP: 120 / 80 mmHg	Max. BP x HR: 20400 mmHg/min	Min. BP x HR: 8050 mmHg/min
Test Termination Criteria: THR achieved		

Protocol Details

Stage Name	Stage Time (min : sec)	Mets	Speed (mph)	Grade (%)	Heart Rate (bpm)	Max. BP (mm/Hg)	Max. ST Level (mm)	Max. ST Slope (mV/s)
Supine	0 : 22	1.0	0	0	126	120 / 80	-1.06 aVR	2.12 V2
Standing	0 : 11	1.0	0	0	124	120 / 80	-1.06 aVR	2.12 V2
Hyperventilation	0 : 12	1.0	0	0	115	120 / 80	-1.06 aVR	2.83 V2
1	3 : 0	4.6	1.7	10	138	120 / 70	-1.27 aVR	3.54 V2
2	3 : 0	7.0	2.5	12	156	120 / 70	-1.49 aVR	4.25 V2
3	3 : 0	10.2	3.4	14	169	120 / 80	-1.70 III	5.31 V2
Peak Ex	0 : 5	13.5	4.2	16	170	120 / 80	-1.70 aVR	5.66 V2
Recovery(1)	1 : 0	1.8	1	0	151	120 / 80	-2.76 aVR	5.66 I
Recovery(2)	1 : 0	1.0	0	0	122	120 / 80	-2.55 aVR	5.66 V2
Recovery(3)	0 : 37	1.0	0	0	120	120 / 80	-1.27 aVR	4.95 V2



VIVEKANAND AROGYA KENDRA

Patient Details

Date: 15-Jun-19

Time: 4:31:28 PM

Name: NIKHIL CHAUDHARY ID: MR008454

Age: 29 y

Sex: M

Height: 244 cms


Weight: 82 Kgs

Interpretation

No significant ST-T changes seen during stress testing.
TMT is negative for stress induced myocardial ischemia seen.
Please correlate clinically.

Ref. Doctor: -----

(Summary Report edited by user)


Doctor: -----
Dr. ARUN KUMAR GARG
MBBS, PGDCC, FNIC, FICC
Consultant Cardiology
Vivekanand Arogya Kendra
Reg. No. HMC-8027