



Kapil
Juneja



BA Continuum India Pvt. Ltd.
A nonbank subsidiary of Bank of America Corporation.

भारत निर्वाचन आयोग
पहचान पत्र
ELECTION COMMISSION OF INDIA
IDENTITY CARD

IMA/1177930



निर्वाचक का नाम : कपिल
Elector's Name : KAPIL
पिता का नाम : सुभाष
Father's Name : SUBHASH
लिंग / Sex : पुरुष / Male
जन्म की तारीख /Date of Birth : 13/10/1989

CERTIFICATE OF MEDICAL FITNESS

This is to certify that I have conducted the clinical examination

of Kapil Duneja on _____

After reviewing the medical history and on clinical examination it has been found that he/she is

	Tick
<ul style="list-style-type: none"> • Medically Fit 	<input type="checkbox"/>
<ul style="list-style-type: none"> • Fit with restrictions/recommendations <p>Though following restrictions have been revealed, in my opinion, these are not impediments to the job.</p> <p>1. <u>Mild anaemia (Microcytic Hypochromic)</u></p> <p>2. <u>Dyslipidaemia with fatty liver Sr?</u></p> <p>3. _____</p> <p>However the employee should follow the advice/medication that has been communicated to him/her.</p> <p>Review after <u>6m</u></p>	<input type="checkbox"/>
<ul style="list-style-type: none"> • Currently Unfit. <p>Review after _____ recommended</p>	<input type="checkbox"/>
<ul style="list-style-type: none"> • Unfit 	<input type="checkbox"/>

Dr. ASHOK K. GUPTA
 Medical Officer
 The Apollo Clinic (Location)
ASHOK K. GUPTA
MBBS, MD
Consulting Physician
Regd. No. 7513 (HMC)

This certificate is not meant for medico-legal purposes

उपलब्ध ओ.पी.डी. सुविधाएँ

- हृदय रोग चिकित्सा
(Cardiology)
- बाल एवं भ्रूण रोग चिकित्सा
(Paediatrics & Fetal Medicine)
- बाल रोग चिकित्सा
(Paediatrics)
- स्त्री रोग चिकित्सा
(Gynaecology)
- हड्डी रोग चिकित्सा
(Orthopaedics)
- दन्त चिकित्सा
(Dental Care)
- सामान्य चिकित्सा
(General Physician)
- फिजियोथैरेपी
(Physiotherapy)
- चर्म रोग चिकित्सा
(Dermatology)
- मूत्र रोग चिकित्सा
(Urology)
- गुर्दा रोग चिकित्सा
(Nephrology)

उपलब्ध जाँच

- डायलिसिस (Dialysis)
- अल्ट्रासाउण्ड (Ultrasound)
- ईको (Echo)
- स्ट्रेस ईको (Stress Echo)
- टी.एम.टी. (T.M.T.)
- पी.एफ.टी. (Lung Function Test)
- ई.सी.जी. (E.C.G.)
- ई.ई.जी. (E.E.G.)
- एक्स-रे (X-Ray)
- मैमोग्राफी (Mammography)
- ओ.पी.जी. (Dental X-Ray)
- हॉल्टर टेस्ट (Holter Test)

Ref. No.:.....

Date:.....

Name of patient: Mr. Kapil Juneja	Age: 30	M/F: M
Consultant:	Speciality: Package	
MR No : MR008437	Visit No: OP017740	Date: 15-06-2019

HTC 5'11"
wt = 80.5kg
Hb: 12.7g/dl
Chest /
Cis /
Abd /

Not for Medico Legal Purpose

रूख एवं मल-मूत्र की जाँच NABL द्वारा मान्यता प्राप्त MolQ लैब द्वारा की जाती है।

सम्पर्क सूत्र: 0124-2224102 / 103 / 104 | Mob.: 8683061905, 8683061906

ओ.पी.डी. पर्ची का शुल्क केवल तीन दिन के लिए मान्य रहेगा।

Radiology Report

Name : Mr. Kapil Juneja
Age/Gender : 30 Y/M
Prescribed Doctor : Self

MR No : MR008437
Visit ID : OP017740
Report Date : 15-06-2019 11:55

Ultrasound

USG EXAMINATION : WHOLE ABDOMEN

Liver shows normal shape with **mild increase in size (15.9cm) with increased echogenicity, suggestive of fatty change with areas of focal fat sparing.** Intrahepatic biliary radicals are not dilated. No focal lesion is seen. **Portal Vein** shows normal calibre.

Gall bladder shows physiological distension and normal wall thickness. No calculus or mass is seen in the lumen.

CBD is normal in diameter. No calculus is seen

Pancreas is normal in size, shape and echo texture.

Spleen is normal in shape, size and echo texture.

Right kidney show normal shape & size. Cortico-medullary differentiation is maintained. Right kidney show no calculus or hydronephrosis.

Left kidney show normal shape & size. Cortico-medullary differentiation is maintained. Left kidney show no calculus or hydronephrosis.


No free fluid is seen in the intra-peritoneal cavity. No evidence of mesenteric lymphadenopathy is seen.

Urinary bladder is partially distended and is normal in shape, size and wall thickness. No mass or calculus is seen.

Prostate is normal in shape, size & echo texture.

IMP : Mild hepatomegaly with fatty liver grade I.

PLEASE CORRELATE CLINICALLY.


Dr. Pawan Joon
MD (Radio-diagnosis)

Radiology Report

Name : Mr. Kapil Juneja
Age/Gender : 30 Y/M
Prescribed Doctor : Self

MR No : MR008437
Visit ID : OP017740
Report Date : 17-06-2019 12:08

X-Ray

X-RAY CHEST PA VIEW

Rotated radiograph.

Bilateral lungs fields are appears to be grossly normal.

Trachea is central.

Both costo phrenic angles and domes of diaphragm are normal.

Cardiac shadows can not be commented upon due to expiratory radiograph.

Soft tissue and bony thoracic cage are normal. *Bifid anterior end of right 5th ribs (normal variant).*

PLEASE CORRELATE CLINICALLY.


DR. PAWAN JOON
MD (Radio-diagnosis)

VIVEKANAND AROGYA KENDRA

Patient Details Date: 15-Jun-19 Time: 2:27:33 PM
Name: KAPIL JUNEJA ID: 8437
Age: 30 y **Sex:** M **Height:** 170 cms **Weight:** 80 Kgs
Clinical History: NOTHING SIGNIFICANT

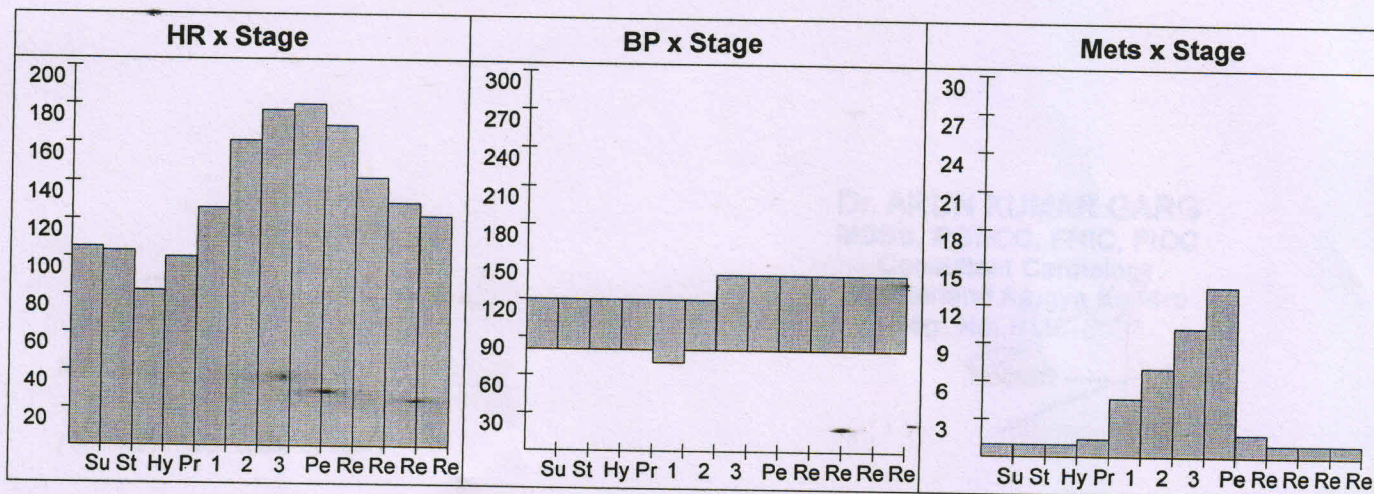
Medications: NIL

Test Details

Protocol: Bruce **Pr.MHR:** 190 bpm **THR:** 161 (85 % of Pr.MHR) bpm
Total Exec. Time: 9 m 16 s **Max. HR:** 180 (95% of Pr.MHR) bpm **Max. Mets:** 13.50
Max. BP: 140 / 80 mmHg **Max. BP x HR:** 25200 mmHg/min **Min. BP x HR:** 5740 mmHg/min
Test Termination Criteria: THR achieved

Protocol Details

Stage Name	Stage Time (min : sec)	Mets	Speed (mph)	Grade (%)	Heart Rate (bpm)	Max. BP (mm/Hg)	Max. ST Level (mm)	Max. ST Slope (mV/s)
Supine	0 : 19	1.0	0	0	105	120 / 80	-1.49 aVR	2.48 II
Standing	0 : 15	1.0	0	0	103	120 / 80	-1.27 aVR	2.48 II
Hyperventilation	0 : 16	1.0	0	0	82	120 / 80	-1.06 aVR	1.77 II
1	3 : 0	4.6	1.7	10	126	120 / 70	-1.49 aVR	3.18 II
2	3 : 0	7.0	2.5	12	161	120 / 80	-1.27 aVR	4.60 V3
3	3 : 0	10.2	3.4	14	177	140 / 80	-1.49 aVR	5.66 II
Peak Ex	0 : 16	13.5	4.2	16	180	140 / 80	-1.49 aVR	5.66 V3
Recovery(1)	1 : 0	1.8	1	0	169	140 / 80	-2.76 aVR	5.66 II
Recovery(2)	1 : 0	1.0	0	0	142	140 / 80	-2.97 aVR	5.66 III
Recovery(3)	1 : 0	1.0	0	0	129	140 / 80	-2.55 aVR	5.66 aVF
Recovery(4)	0 : 29	1.0	0	0	122	140 / 80	-1.49 aVR	4.25 II



VIVEKANAND AROGYA KENDRA

Patient Details

Date: 15-Jun-19

Time: 2:27:33 PM

Name: KAPIL JUNEJA ID: 8437

Age: 30 y

Sex: M

Height: 170 cms

Weight: 80 Kgs

Interpretation

No significant ST-T changes seen during TMT.
TMT is negative for stress induced myocardial ischemia seen.
Please correlate clinically.

Dr. ARUN KUMAR GARG
MBBS, PGDCC, FNIC, FICC
Consultant Cardiology
Vivekanand Arogya Kendra
Reg. No. 11110-8027

Doctor: -----

Ref. Doctor: -----

(Summary Report edited by user)