

Akrant Kumar
Jaiswal



BA Continuum India Pvt. Ltd.
A nonbank subsidiary of Bank of America Corporation

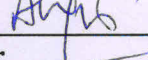
CERTIFICATE OF MEDICAL FITNESS

This is to certify that I have conducted the clinical examination

of Akramant Kumar Jaiswal on _____

After reviewing the medical history and on clinical examination it has been found that he/she is

	Tick
<ul style="list-style-type: none"> • Medically Fit 	<input type="checkbox"/>
<ul style="list-style-type: none"> • Fit with restrictions/recommendations <p>Though following restrictions have been revealed, in my opinion, these are not impediments to the job.</p> <p>1. <u>Hyperuricemia</u>.....</p> <p>2. <u>Dyslipidemia with Fatty Liver Sr 2</u>.....</p> <p>3. <u>Abnormal LFT - Mild raised S. Bilirubin</u>.....</p> <p>However the employee should follow the advice/medication that has been communicated to him/her.</p> <p>Review after <u>1 m.</u></p>	<input type="checkbox"/>
<ul style="list-style-type: none"> • Currently Unfit. <p>Review after _____ recommended</p>	<input type="checkbox"/>
<ul style="list-style-type: none"> • Unfit 	<input type="checkbox"/>

Dr. 
Medical Officer
The Apollo Clinic, (Location)

Dr. ASHOK K. GUPTA
MBBS, MD
Consulting Physician
Regd. No. 7513 (HMC)

This certificate is not meant for medico-legal purposes

उपलब्ध ओ.पी.डी. सुविधाएँ

- हृदय रोग चिकित्सा
(Cardiology)
- बाल एवं भ्रूण रोग चिकित्सा
(Paediatrics & Fetal Medicine)
- बाल रोग चिकित्सा
(Paediatrics)
- स्त्री रोग चिकित्सा
(Gynaecology)
- हड्डी रोग चिकित्सा
(Orthopaedics)
- दन्त चिकित्सा
(Dental Care)
- सामान्य चिकित्सा
(General Physician)
- फिजियोथैरेपी
(Physiotherapy)
- चर्म रोग चिकित्सा
(Dermatology)
- मूत्र रोग चिकित्सा
(Urology)
- गुर्दा रोग चिकित्सा
(Nephrology)

उपलब्ध जाँच

- डायलिसिस (Dialysis)
- अल्ट्रासाउण्ड (Ultrasound)
- ईको (Echo)
- स्ट्रेस ईको (Stress Echo)
- टी.एम.टी. (T.M.T.)
- पी.एफ.टी. (Lung Function Test)
- ई.सी.जी. (E.C.G.)
- ई.ई.जी. (E.E.G.)
- एक्स-रे (X-Ray)
- मैमोग्राफी (Mammography)
- ओ.पी.जी. (Dental X-Ray)
- हॉल्टर टेस्ट (Holter Test)

Ref. No.:.....

Date:.....

Name of patient: Mr. Akrant Kumar Jaiswal	Age: 33	M/F: M
Consultant:	Speciality: Package	
MR No : MR008422	Visit No: OP017708	Date: 15-06-2019

HT = 5'11"
 Wt = 89.8 kg
 BP = 78/110
 Bp = 120/76 mmHg
 Chest |
 CVS |
 Abd |

Not for Medico Legal Purpose

खून एवं मल-मूत्र की जाँच NABL द्वारा मान्यता प्राप्त MoIQ लैब द्वारा की जाती है।

सम्पर्क सूत्र: 0124-2224102 / 103 / 104 | Mob.: 8683061905, 8683061906

ओपीडी. पर्ची का शुल्क केवल तीन दिन के लिए मान्य रहेगा।

Radiology Report

Name : Mr. Akrant Kumar Jaiswal
Age/Gender : 33 Y/M
Prescribed Doctor : Self

MR No : MR008422
Visit ID : OP017708
Report Date : 15-06-2019 12:16

Ultrasound

USG EXAMINATION : WHOLE ABDOMEN

Liver shows normal shape with mild increase in size (15.8cm) with increased echogenicity, suggestive of fatty change. Intrahepatic biliary radicals are not dilated. No focal lesion is seen. **Portal Vein** shows normal calibre.

Gall bladder shows physiological distension and normal wall thickness. No calculus or mass is seen in the lumen.

CBD is normal in diameter. No calculus is seen

Pancreas is normal in size, shape and echo texture.

Spleen is normal in shape, size and echo texture.

Right kidney show normal shape & size. Cortico-medullary differentiation is maintained. Right kidney show no calculus or hydronephrosis.

Left kidney show normal shape & size. Cortico-medullary differentiation is maintained. Left kidney show no calculus or hydronephrosis.


No free fluid is seen in the intra-peritoneal cavity. No evidence of mesenteric lymphadenopathy is seen.

Urinary bladder is normal in shape, size and wall thickness. No mass or calculus is seen.

Prostate is normal in shape, size & echo texture. Volume of prostate is 20cc.

IMP : Mild hepatomegaly with fatty liver grade I.

PLEASE CORRELATE CLINICALLY.


Dr. Pawan Joon
MD (Radio- diagnosis)

Radiology Report

Name : Mr. Akrant Kumar Jaiswal
Age/Gender : 33 Y/M
Prescribed Doctor : Self

MR No : MR008422
Visit ID : OP017708
Report Date : 17-06-2019 12:34

X-Ray

X-RAY CHEST PA VIEW

Rotated radiograph.

Bilateral lung fields appears to be clear. No obvious pulmonary parenchymal lesion is seen.


Trachea is central.

Cardiac configuration appears to be normal with normal cardio-thoracic ratio.

Both costo phrenic angles and domes of diaphragm are normal.

Visualized soft tissue and bony thoracic cage appears to be normal.

PLEASE CORRELATE CLINICALLY.



DR. PAWAN JOON
MD (Radio-diagnosis)

VIVEKANAND AROGYA KENDRA

Patient Details **Date:** 15-Jun-19 **Time:** 12:33:50 PM
Name: Akrant Jaiswal ID: 008422
Age: 33 y **Sex:** M **Height:** 71 ins **Weight:** 90 Kgs
Clinical History: nothing significant

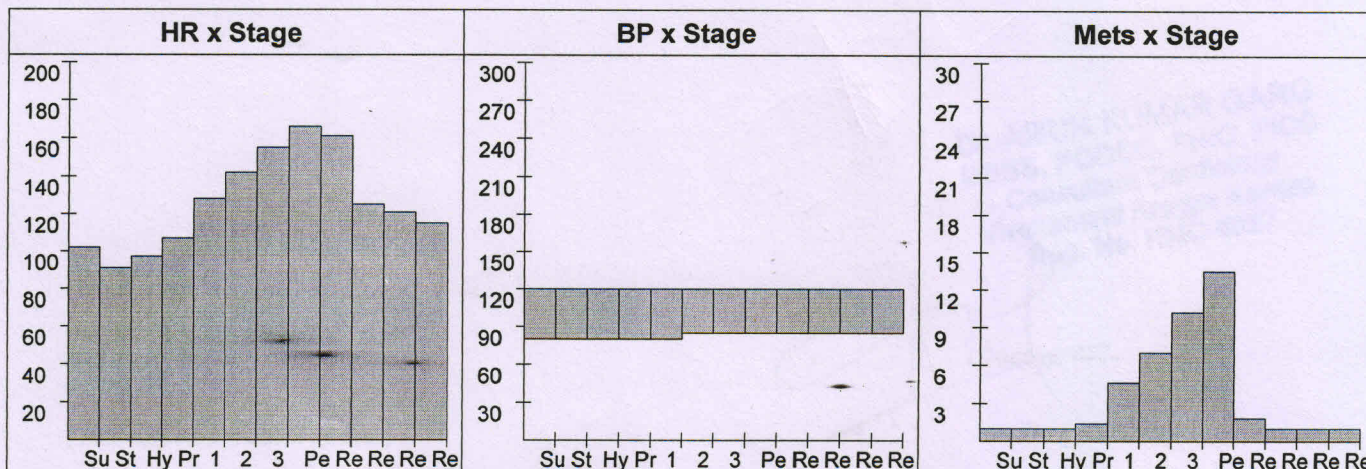
Medications: nil

Test Details

Protocol: Bruce **Pr.MHR:** 187 bpm **THR:** 158 (85 % of Pr.MHR) bpm
Total Exec. Time: 9 m 29 s **Max. HR:** 166 (89% of Pr.MHR)bpm **Max. Mets:** 13.50
Max. BP: 120 / 80 mmHg **Max. BP x HR:** 19920 mmHg/min **Min. BP x HR:** 7280 mmHg/min
Test Termination Criteria: THR achieved

Protocol Details

Stage Name	Stage Time (min : sec)	Mets	Speed (mph)	Grade (%)	Heart Rate (bpm)	Max. BP (mm/Hg)	Max. ST Level (mm)	Max. ST Slope (mV/s)
Supine	0 : 39	1.0	0	0	102	120 / 80	-1.27 aVR	2.83 V3
Standing	0 : 40	1.0	0	0	91	120 / 80	-1.49 aVR	2.83 V3
Hyperventilation	0 : 16	1.0	0	0	97	120 / 80	-1.27 aVR	2.83 V3
1	3 : 0	4.6	1.7	10	128	120 / 80	-1.49 aVR	3.54 V3
2	3 : 0	7.0	2.5	12	142	120 / 85	-1.49 aVR	3.89 V4
3	3 : 0	10.2	3.4	14	155	120 / 85	-1.27 aVR	4.95 V4
Peak Ex	0 : 29	13.5	4.2	16	166	120 / 85	-1.27 V1	4.60 V4
Recovery(1)	1 : 0	1.8	1	0	161	120 / 85	-1.70 aVR	5.66 V3
Recovery(2)	1 : 0	1.0	0	0	125	120 / 85	-2.12 aVR	5.31 V3
Recovery(3)	1 : 0	1.0	0	0	121	120 / 85	-2.12 aVR	3.89 V4
Recovery(4)	0 : 41	1.0	0	0	115	120 / 85	-0.85 aVR	2.48 V4



VIVEKANAND AROGYA KENDRA

Patient Details

Date: 15-Jun-19

Time: 12:33:50 PM

Name: Akrant Jaiswal ID: 008422

Age: 33 y

Sex: M

Height: 71 ins

Weight: 90 Kgs

Interpretation

No ST-T significant changes seen during stress TMT.
TMT is negative for stress induced myocardial ischemia seen.
Please corelate clinically.

Dr. ARUN KUMAR GARG
MBBS, PGDCC, FNIC, FICC
Consultant Cardiology
Vivekanand Arogya Kendra
Reg. No. HMC-8027

Ref. Doctor: -----


Doctor: -----

(Summary Report edited by user)