

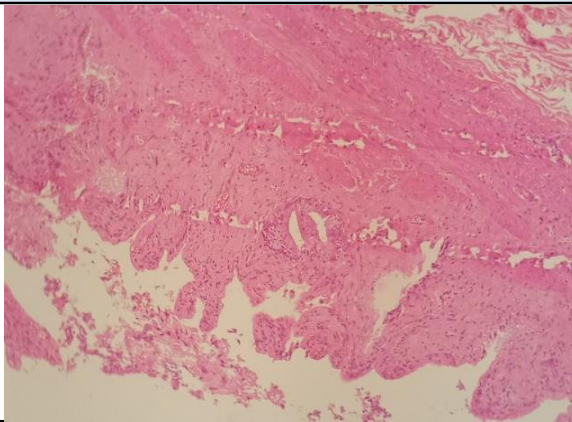
Patient Name	Mrs. RANJITA	Client Name	Chiranjeev Path Lab	Specimen Received	12/06/19
Age/Sex	38 Years/Female			Specimen Type	Tissue
Patient ID	011906120094			Collection Date	12/06/19
Specimen ID	MOLQ/B-1104/19			Report Date	17/06/19

SURGICAL PATHOLOGY REPORT

Gall bladder

DIAGNOSIS

CHOLECYSTITIS WITH CHOLELITHIASIS



SPECIMEN

Gall bladder

GROSS

Received 6.2x2.8cm long gall bladder already cut open without stones.

Microscopy

Section examined shows ulcerative mucosa and Rokitansky Aschoff sinuses (irregularly shaped tubular structures lined by cuboidal lining epithelium with round to oval nucleus) with fibrocollagenous tissue and inflammatory cells (lymphocytes).

Note : All biopsy specimen will be stored for 15 (fifteen) days, block and slides for 5 (five) years only from the time of receipt at the laboratory. No request, for any of the above, will be entertained after the due date.

Reference

- i) Rosai and Ackerman's Surgical Pathology.
- ii) Modern Surgical Pathology.

Gulshan Yadav, MD
Consultant Pathologist