

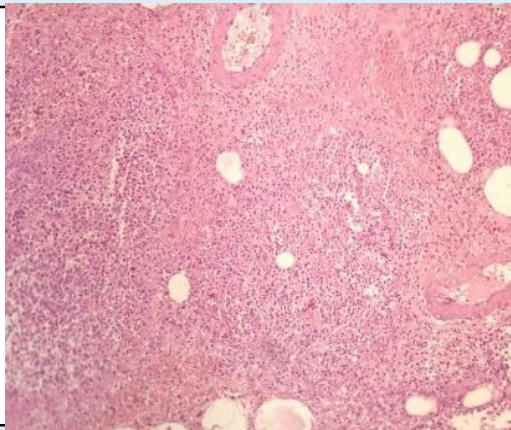
Patient Name	MOHIT	Client Name	MolQ Collection Centre CSK	Specimen Received	31/05/19
Age/Sex	17 YRS/M	Hospital, Sohna		Specimen Type	Tissue
Patient ID	011905310284			Collection Date	31/05/19
Specimen ID	MOLQ/B-1022/19			Report Date	17/06/19

SURGICAL PATHOLOGY REPORT

Appendix

DIAGNOSIS

ACUTE APPENDICITIS



SPECIMEN

Appendix

GROSS

Received 7x0.5cm greyish white tissue piece.

Microscopy

Section examined shows lymphoid follicles with ulcerative mucosa. Deeper tissue shows inflammatory cells (polymorphs, lymphocytes and few histiocytes).

Note : All biopsy specimen will be stored for 15 (fifteen)days, block and slides for 5(five) years only from the time of receipt at the laboratory. No request ,for any of the above ,will be entertained after the due date.

Reference

- i) Rosai and Ackerman's Surgical Pathology.
- ii) Modern Surgical Pathology.

Gulshan Yadav, MD
Consultant Pathologist