

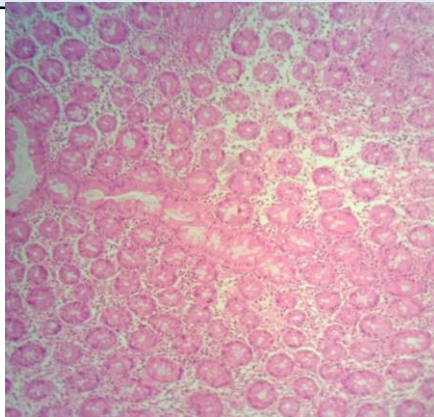
Patient Name	Mrs. SASHI MISHRA	Client Name	Medi Quick Path Lab 2,	Specimen Received	11/06/19
Age/Sex	72 Years/Female	Gurgaon		Specimen Type	Tissue
Patient ID	011906110293			Collection Date	11/06/19
Specimen ID	MOLQ/B-1092/19(A)			Report Date	15/06/19

SURGICAL PATHOLOGY REPORT

Cecum ulcer biopsy

DIAGNOSIS

Non Specific Inflammation.



SPECIMEN

Cecum ulcer biopsy

GROSS

Received one block and one slide labelled as S-3317/19.

Microscopy

Section examined shows mucosal lining epithelium with columnar cells having round nucleus. Submucosal shows glands and inflammatory cells(Lymphocyte and few Polymorphs). No granuloma and no malignant cells seen.

Note : All biopsy specimen will be stored for 15 (fifteen)days, block and slides for 5(five) years only from the time of receipt at the laboratory. No request ,for any of the above ,will be entertained after the due date.

Reference

- i) Rosai and Ackerman's Surgical Pathology.
- ii) Modern Surgical Pathology.



Gulshan Yadav, MD
Consultant Pathologist