

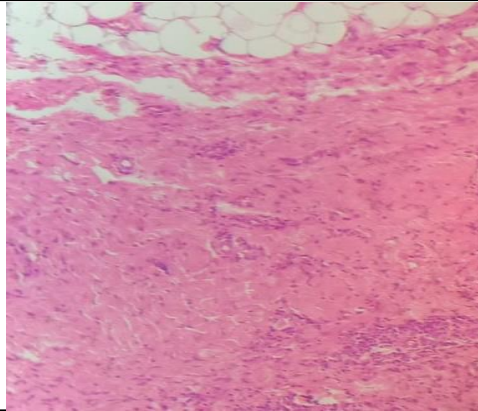
Patient Name	Mrs. MANJEET KAUR	Client Name	Lifeaid Wellness Centre	Specimen Received	10/06/19
Age/Sex	30 Years/Female			Specimen Type	Tissue
Patient ID	011906100085			Collection Date	10/06/19
Specimen ID	MOLQ/B-1084/19			Report Date	14/06/19

SURGICAL PATHOLOGY REPORT

Endometrial polyp

DIAGNOSIS

Endometrial polyp



SPECIMEN

Endometrial polyp

GROSS

Received multiple greyish white tissue piece.

Microscopy

Section examined shows mucosal lining epithelium small and tortous endometrial glands with columnar lining epithelium small round nucleus.

Stroma shows mononuclear inflammatory cells.

Note : All biopsy specimen will be stored for 15 (fifteen)days, block and slides for 5(five) years only from the time of receipt at the laboratory. No request ,for any of the above ,will be entertained after the due date.

Reference

- i) Rosai and Ackerman's Surgical Pathology.
- ii) Modern Surgical Pathology.

Gulshan Yadav, MD
Consultant Pathologist