

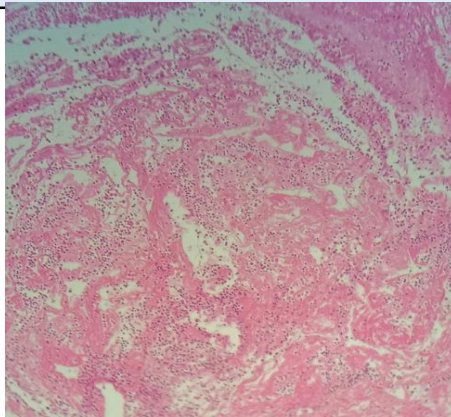
Patient Name	Mrs. SURESH 32137	Client Name	Pushpanjali Hospital	Specimen Received	08/06/19
Age/Sex	57 Years/Female	(Rewari)		Specimen Type	Tissue
Patient ID	011906080221			Collection Date	08/06/19
Specimen ID	MOLQ/B-1071/19			Report Date	14/06/19

SURGICAL PATHOLOGY REPORT

Endometrial biopsy

DIAGNOSIS

Hyperprogesteric Effect



SPECIMEN

Endometrial biopsy

GROSS

Received multiple greyish white tissue piece.

Microscopy

Section examined shows decidual cells, RBCs, fibrin and inflammatory cells and blood clot with degenerated cells and (autolytic changes).

No granuloma and no malignant cells seen.

Note : All biopsy specimen will be stored for 15 (fifteen)days, block and slides for 5(five) years only from the time of receipt at the laboratory. No request ,for any of the above ,will be entertained after the due date.

Reference

- i) Rosai and Ackerman's Surgical Pathology.
- ii) Modern Surgical Pathology.



Gulshan Yadav, MD
Consultant Pathologist