

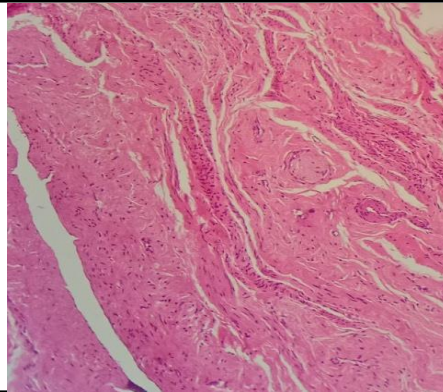
Patient Name	Mrs. RAM WATI	Client Name	Life Care Path Lab, Tauru	Specimen Received	09/06/19
Age/Sex	50 YRS/F			Specimen Type	Tissue
Patient ID	011906090243			Collection Date	09/06/19
Specimen ID	MOLQ/B-1079/19			Report Date	12/06/19

SURGICAL PATHOLOGY REPORT

Gall Bladder

DIAGNOSIS

CHOLECYSTITIS WITH CHOLELITHIASIS



SPECIMEN

Gall Bladder

GROSS

Received 8.7x3cm long gallbladder cut section shows stones.

Microscopy

Section examined shows ulcerative mucosa and Rokitansky-Aschoff sinuses (irregularly shaped tubular structures lined by cuboidal lining epithelium with round to oval nucleus) with fibrocollagenous tissue and inflammatory cells (lymphocytes).

Note : All biopsy specimen will be stored for 15 (fifteen) days, block and slides for 5 (five) years only from the time of receipt at the laboratory. No request, for any of the above, will be entertained after the due date.

Reference

- i) Rosai and Ackerman's Surgical Pathology.
- ii) Modern Surgical Pathology.

Gulshan Yadav, MD
Consultant Pathologist