

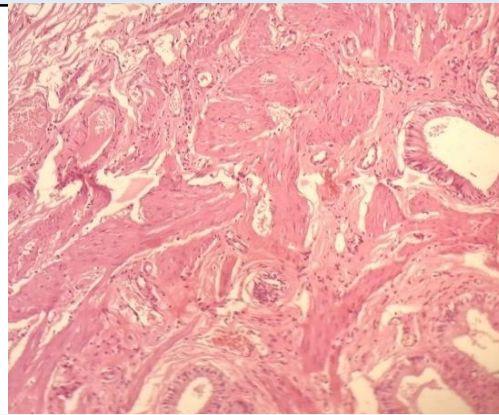
Patient Name	Mr. MUDASSIR AH /SOPORE	Specimen Received	28/05/2019
Age/Sex	28 YRS/M	Specimen Type	Tissue
Patient ID	011905280418	Client Name	Bandipora Collection Centre, Jammu & Kashmir
Specimen ID	MOLQ/B-997/19	Collection Date	28/05/2019
		Report Date	13/06/2019

SURGICAL PATHOLOGY REPORT

Gall bladder

DIAGNOSIS

CHOLECYSTITIS WITH CHOLELITHIASIS



SPECIMEN

Gall bladder

GROSS

Received 4x2.8cm long gallbladder cut section shows stones.

Microscopy

Section examined shows ulcerative mucosa and Rokitansky-Aschoff sinuses (irregularly shaped tubular structures lined by cuboidal lining epithelium with round to oval nucleus) with fibrocollagenous tissue and inflammatory cells (lymphocytes).

Note : All biopsy specimen will be stored for 15 (fifteen) days, block and slides for 5 (five) years only from the time of receipt at the laboratory. No request, for any of the above, will be entertained after the due date.

Reference

- i) Rosai and Ackerman's Surgical Pathology.
- ii) Modern Surgical Pathology.

Gulshan Yadav, MD
Consultant Pathologist