

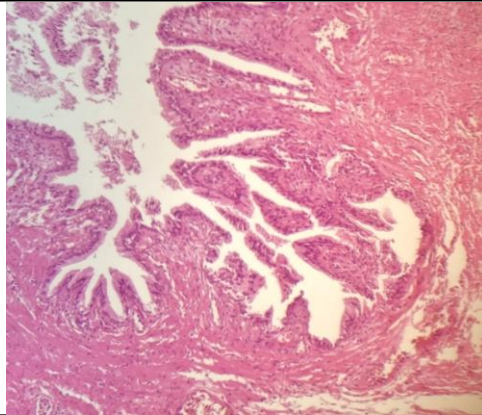
Patient Name	KANWAR SINGH -31562	Client Name	Pushpanjali Hospital (Rewari)	Specimen Received	07/06/2019
Age/Sex	65 YRS/M			Specimen Type	Tissue
Patient ID	011906070231			Collection Date	07/06/2019
Specimen ID	MOLQ/B-1063/19			Report Date	11/06/2019

SURGICAL PATHOLOGY REPORT

TRUP chips

DIAGNOSIS

BENIGN PROSTATIC HYPERPLASIA



SPECIMEN

TRUP chips

GROSS

Received 5x6cm greyish white tissue piece in aggregate weigh 12 gram.

Microscopy

Section examined shows bilayered prostatic glands with columnar lining epithelium and with small round to oval nucleus surrounded by large number of fibrocollagenous tissue and mononuclear inflammatory cell.

Note : All biopsy specimen will be stored for 15 (fifteen) days, block and slides for 5 (five) years only from the time of receipt at the laboratory. No request ,for any of the above will be entertained after the due date.

Reference

- Rosai and Ackerman's Surgical Pathology.
- Modern Surgical Pathology.



Gulshan Yadav, MD
Consultant Pathologist