

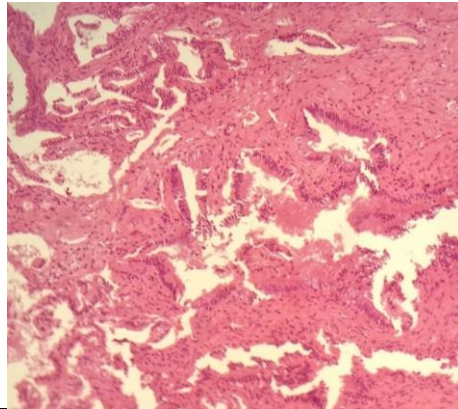
Patient Name	Ms. KULSOOMA 437	Client Name	Apollo Laboratories CC, Jammu	Specimen Received	05/06/19
GULGAM		& Kashmir		Specimen Type	Tissue
Age/Sex	28 Years/Female			Collection Date	05/06/19
Patient ID	011906050093			Report Date	11/06/19
Specimen ID	MOLQ/B-1054/19				

SURGICAL PATHOLOGY REPORT

Gall bladder

DIAGNOSIS

CHOLECYSTITIS



SPECIMEN

Gall bladder

GROSS

Received 7x2.5cm long gallbladder cut section shows no stones.

Microscopy

Section examined shows ulcerative mucosa and Rokitansky Aschoff sinus (irregularly shaped tubular structures lined by cuboidal lining epithelium with round to oval nucleus) with fibro collagenous tissue and inflammatory cells (lymphocytes).

Note : All biopsy specimen will be stored for 15 (fifteen) days, block and slides for 5 (five) years only from the time of receipt at the laboratory. No request, for any of the above, will be entertained after the due date.

Reference

- i) Rosai and Ackerman's Surgical Pathology.
- ii) Modern Surgical Pathology.

Gulshan Yadav, MD
Consultant Pathologist