

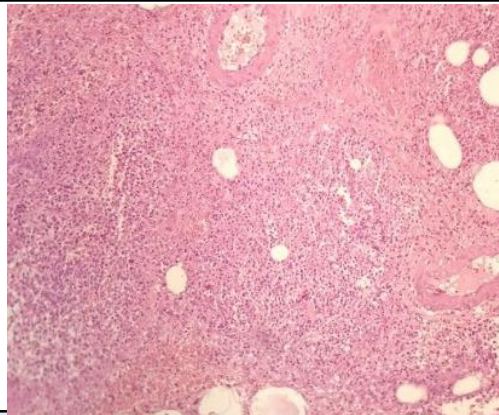
Patient Name	Mrs. USHA CHHETRI	Client Name	Lifeaid Wellness Centre	Specimen Received	04/06/19
Age/Sex	27 Years/Female			Specimen Type	Tissue
Patient ID	011906040076			Collection Date	04/06/19
Specimen ID	MOLQ/B-1042/19			Report Date	11/06/19

SURGICAL PATHOLOGY REPORT

Appendix

DIAGNOSIS

ACUTE APPENDICITIS



SPECIMEN

Appendix

GROSS

Received 6.9x1.2cm long appendix cut section shows fecolith.

Microscopy

Section examined shows lymphoid follicles with ulcerative mucosa. Deeper tissue shows inflammatory cells (polymorphs, lymphocytes and few histiocytes).

Note : All biopsy specimen will be stored for 15 (fifteen)days, block and slides for 5(five) years only from the time of receipt at the laboratory. No request ,for any of the above ,will be entertained after the due date.

Reference

- i) Rosai and Ackerman's Surgical Pathology.
- ii) Modern Surgical Pathology.

Gulshan Yadav, MD
Consultant Pathologist