

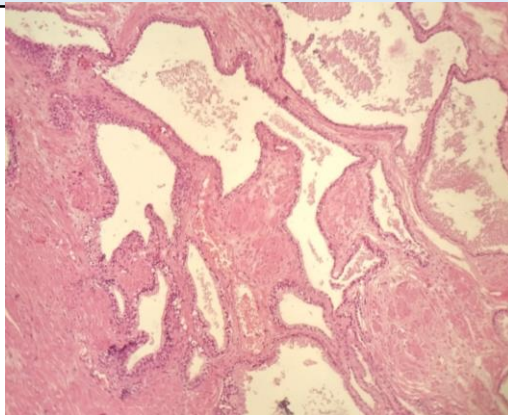
Patient Name	Mr. PALA RAM 3211	Client Name	Pushpanjali Hospital (Rewari)	Specimen Received	03/06/19
Age/Sex	80 Years/Male			Specimen Type	Tissue
Patient ID	011906030175			Collection Date	03/06/19
Specimen ID	MOLQ/B-1038/19			Report Date	11/06/19

SURGICAL PATHOLOGY REPORT

TURP chips

DIAGNOSIS

BENIGN PROSTATIC HYPERPLASIA



SPECIMEN

TURP chips

GROSS

Received multiple greyish white tissue piece measuring 5x4cm and weigh 20 gram.

Microscopy

Section examined shows bilayered prostatic glands with columnar lining epithelium and with small round to oval nucleus surrounded by large number of fibrocollagenous tissue and mononuclear inflammatory cell.

Note : All biopsy specimen will be stored for 15 (fifteen)days, block and slides for 5(five) years only from the time of receipt at the laboratory. No request ,for any of the above ,will be entertained after the due date.

Reference

- i) Rosai and Ackerman's Surgical Pathology.
- ii) Modern Surgical Pathology.

Gulshan Yadav, MD
Consultant Pathologist