

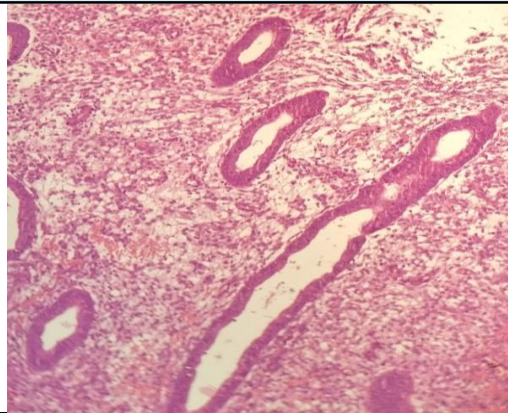
Patient Name	Ms. NEELAM	Client Name	Global Diagnostic Center, Tauru	Specimen Received	03/06/19
Age/Sex	27 Years/Female			Specimen Type	Tissue
Patient ID	011906030167			Collection Date	03/06/19
Specimen ID	MOLQ/B-1039/19			Report Date	11/06/19

SURGICAL PATHOLOGY REPORT

Endometrium

DIAGNOSIS

Proliferative Phase.



SPECIMEN

Endometrium

GROSS

Received multiple greyish white tissue piece.

Microscopy

Section examined shows endometrial glands with columnar lining epithelium with round to oval nucleus stroma shows mononuclear inflammatory cells seen. No granuloma and no malignant cells seen.

Note : All biopsy specimen will be stored for 15 (fifteen)days, block and slides for 5(five) years only from the time of receipt at the laboratory. No request ,for any of the above ,will be entertained after the due date.

Reference

- i) Rosai and Ackerman's Surgical Pathology.
- ii) Modern Surgical Pathology.

Gulshan Yadav, MD
Consultant Pathologist