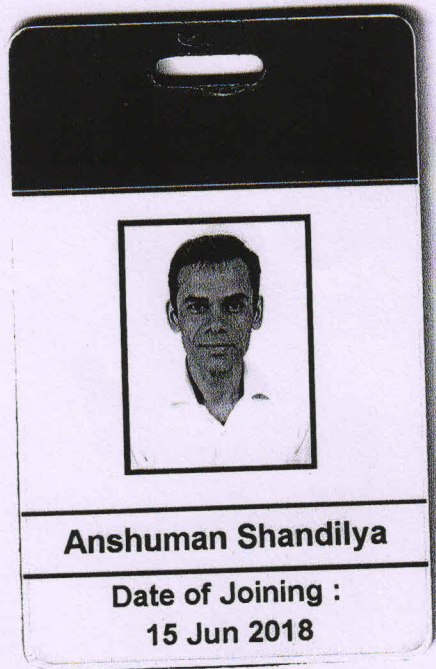


Anshuman Shandilya

**Date of Joining :
15 Jun 2018**



accenture



Anshuman Shandilya

11563833

CERTIFICATE OF MEDICAL FITNESS

This is to certify that I have conducted the clinical examination

of Anshuman on _____

After reviewing the medical history and on clinical examination it has been found that he/she is

<ul style="list-style-type: none"> • Medically Fit 	Tick
<ul style="list-style-type: none"> • Fit with restrictions/recommendations <p>Though following restrictions have been revealed, in my opinion, these are not impediments to the job.</p> <p>1. <u>Dyslipidemic</u></p> <p>2. <u>Vit D - Deficiency</u></p> <p>3. <u>Low Serum Sodium level</u></p> <p>However the employee should follow the advice/medication that has been communicated to him/her.</p> <p>Review after <u>15d</u></p>	
<ul style="list-style-type: none"> • Currently Unfit. <p>Review after _____ recommended</p>	
<ul style="list-style-type: none"> • Unfit 	

Dr. AS
 Medical Officer
 The Apollo Clinic (Location)

DR. ASHOK K. GUPTA
MBBS, MD
Consulting Physician
Regd. No. 7513 (HMC)

This certificate is not meant for medico-legal purposes

उपलब्ध ओ.पी.डी. सुविधाएँ

- हृदय रोग चिकित्सा
(Cardiology)
- बाल एवं भ्रूण रोग चिकित्सा
(Paediatrics & Fetal Medicine)
- बाल रोग चिकित्सा
(Paediatrics)
- स्त्री रोग चिकित्सा
(Gynaecology)
- हड्डी रोग चिकित्सा
(Orthopaedics)
- दन्त चिकित्सा
(Dental Care)
- सामान्य चिकित्सा
(General Physician)
- फिजियोथैरेपी
(Physiotherapy)
- चर्म रोग चिकित्सा
(Dermatology)
- मूत्र रोग चिकित्सा
(Urology)
- गुर्दा रोग चिकित्सा
(Nephrology)

उपलब्ध जाँच

- डायलिसिस (Dialysis)
- अल्ट्रासाउण्ड (Ultrasound)
- ईको (Echo)
- स्ट्रेस ईको (Stress Echo)
- टी.एम.टी. (T.M.T.)
- पी.एफ.टी. (Lung Function Test)
- ई.सी.जी. (E.C.G.)
- ई.ई.जी. (E.E.G.)
- एक्स-रे (X-Ray)
- मैमोग्राफी (Mammography)
- ओ.पी.जी. (Dental X-Ray)
- हॉल्टर टेस्ट (Holter Test)

Ref. No.:.....

Date:.....

Name of patient: Mr. Anshuman	Age: 41	M/F: M
Consultant:	Speciality: Package	
MR No : MR007809	Visit No: OP016354	Date: 01-06-2019

Vision : distant } 6/6 (Right)
5/6 (Left)
Near - N-5
Colour - Normal

Ht = 5'6"

Wt. 51.3 kg

PR = 72/mt

BP = 120/70 mm Hg

Chest |
Cvs |
Abd |

Not for Medico Legal Purpose

रून एवं मल-मूत्र की जाँच NABL द्वारा मान्यता प्राप्त MoIQ लैब द्वारा की जाती है।

सम्पर्क सूत्र: 0124-2224102 / 103 / 104 | Mob.: 8683061905, 8683061906

ओ.पी.डी. पर्ची का शुल्क केवल तीन दिन के लिए मान्य रहेगा।

Radiology Report

Name : Mr. Anshuman
Age/Gender : 41 Y/M
Prescribed Doctor : Self

MR No : MR007809
Visit ID : OP016354
Report Date : 01-06-2019 11:57

Ultrasound

USG EXAMINATION : WHOLE ABDOMEN

Liver shows normal shape and size with homogenous echo texture. Intrahepatic biliary radicals are not dilated. No focal lesion is seen. **Portal Vein** shows normal calibre.

Gall bladder shows physiological distension and normal wall thickness. No calculus or mass is seen in the lumen.

CBD is normal in diameter. No calculus is seen

Pancreas is normal in size, shape and echo texture.

Spleen is normal in shape, size and echo texture.

Right kidney show normal shape & size. Cortico-medullary differentiation is maintained. Right kidney show no calculus or hydronephrosis.

Left kidney show normal shape & size. Cortico-medullary differentiation is maintained. Left kidney show no calculus or hydronephrosis.


No free fluid is seen in the intra-peritoneal cavity. No evidence of mesenteric lymphadenopathy is seen.

Urinary bladder is over distended and is normal in shape, size and wall thickness. No mass or calculus is seen.

Prostate is normal in shape, size & echo texture. Volume of prostate is 18cc.

IMP: Normal study.

PLEASE CORRELATE CLINICALLY.


Dr. Pawan Joon
MD (Radio- diagnosis)



विवेकानन्द आरोग्य केन्द्र

डायग्नोस्टिक एवं ओपीडी
भारत विकास परिषद्, महाराष्ट्र प्रताप न्यास द्वारा संचालित



Radiology Report

Name : Mr. Anshuman
Age/Gender : 41 Y/M
Prescribed Doctor : Self

MR No : MR007809
Visit ID : OP016354
Report Date : 03-06-2019 13:41

X-Ray

X-RAY CHEST PA VIEW

Bilateral lung fields appears to be clear. No obvious pulmonary parenchymal lesion is seen.


Trachea is central.

Cardiac configuration appears to be normal with normal cardio-thoracic ratio.

Both costo phrenic angles and domes of diaphragm are normal.

Visualized soft tissue and bony thoracic cage appears to be normal.

PLEASE CORRELATE CLINICALLY.


DR. PAWAN JOON
MD (Radio-diagnosis)

ID: 00007809

01-06-2019 12:29:28

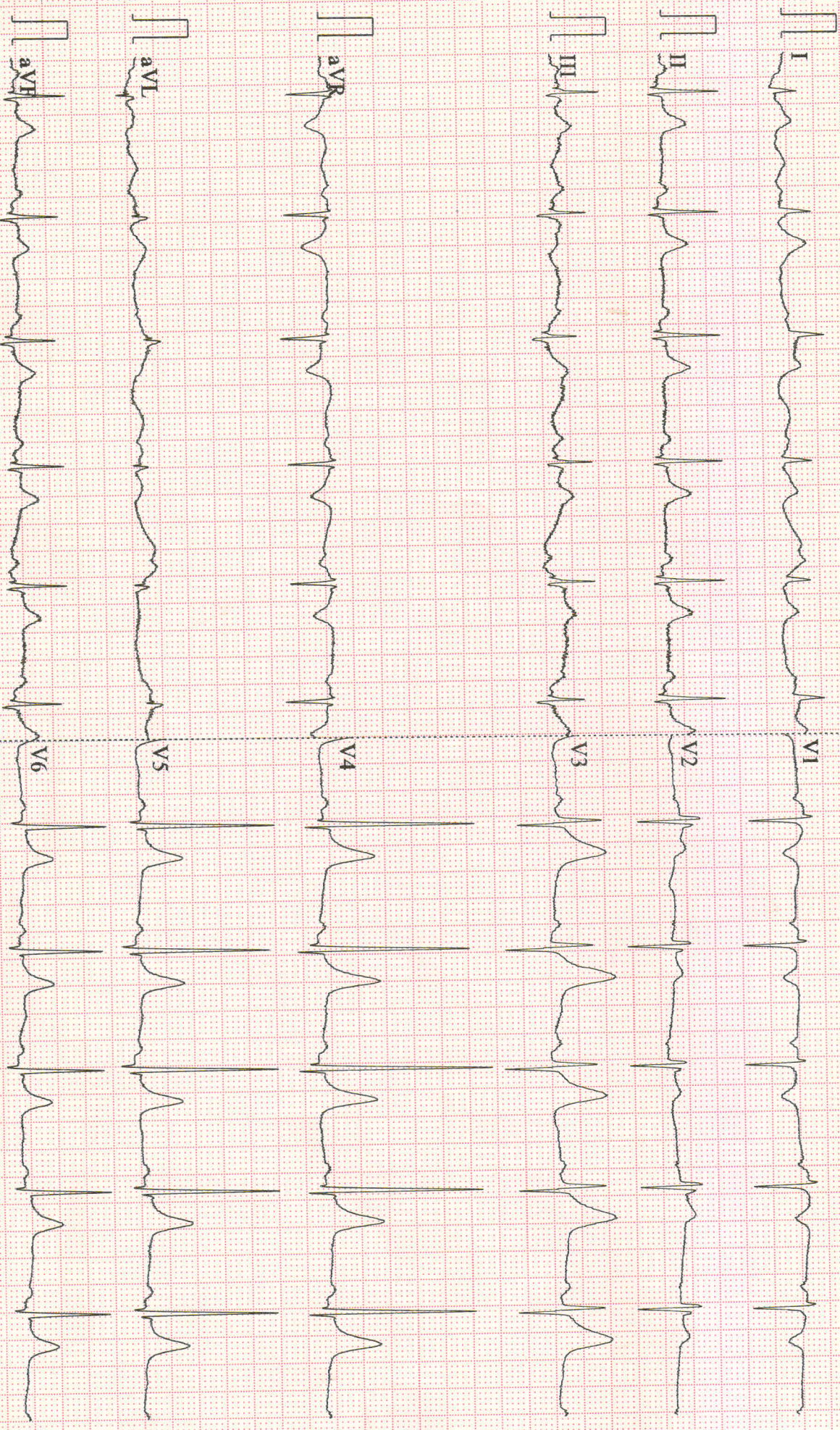
mr anshuman
Male 41Years

HR	: 67	bpm
P	: 102	ms
PR	: 164	ms
QRS	: 92	ms
QT/QTc	: 372/393	ms
P/QRS/T	: 65/50/58	°
RV5/SV1	: 2.45/0.955	mV

Diagnosis Information:

Sinus Rhythm
 Larged PtfV1
 Slight ST Elevation(V4,V5,V6)

Report Confirmed by:



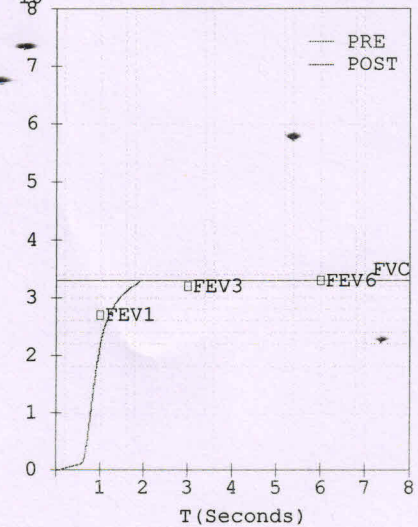
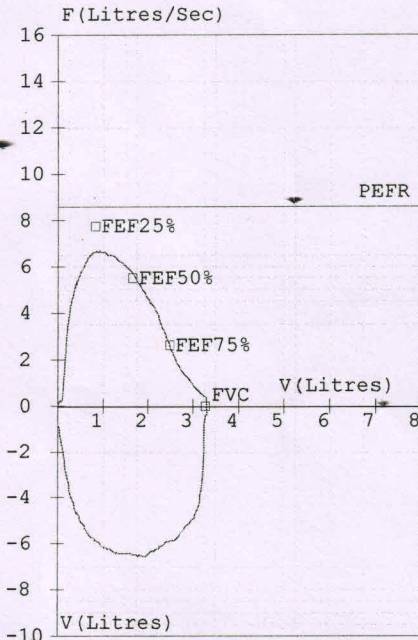
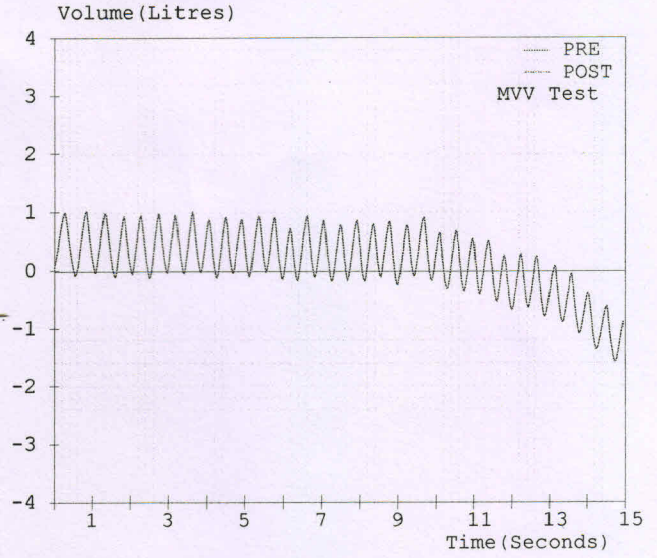
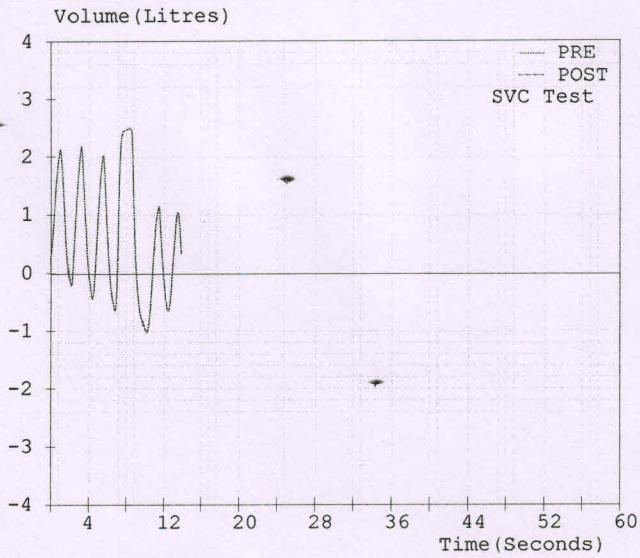
VIVEKANAND AROGYA KENDRA

466 P, SECTOR 12 A, GURGAON-122001 PHONE 0124-2224102-104

Patient: MR ANSHUMAN
 Refd.By:
 Pred.Eqns: RECORDERS
 Date : 01-Jun-2019 10:23 AM

Age : 41 Yrs
 Height : 167 Cms
 Weight : 51 Kgs
 ID : 007809

Gender : Male
 Smoker : No
 Eth. Corr: 100
 Temp :



Spirometry Results

Parameter	Pred	M.Pre	%Pred	M.Post	%Pred	%Imp
FVC (L)	03.29	03.29	100	-----	---	---
FEV1 (L)	02.69	02.30	086	-----	---	---
FEV1/FVC (%)	81.76	69.91	086	-----	---	---
FEF25-75 (L/s)	03.84	04.91	128	-----	---	---
PEFR (L/s)	08.60	06.61	077	-----	---	---
FIVC (L)	-----	03.40	---	-----	---	---
FEV.5 (L)	-----	00.10	---	-----	---	---
FEV3 (L)	03.19	03.29	103	-----	---	---
PIFR (L/s)	-----	06.50	---	-----	---	---
FEF75-85 (L/s)	-----	01.84	---	-----	---	---
FEF.2-1.2 (L/s)	06.67	05.64	085	-----	---	---
FEF 25% (L/s)	07.76	06.54	084	-----	---	---
FEF 50% (L/s)	05.51	05.65	103	-----	---	---
FEF 75% (L/s)	02.64	02.59	098	-----	---	---
FEV.5/FVC (%)	-----	03.04	---	-----	---	---
FEV3/FVC (%)	96.96	100.00	103	-----	---	---
FET (Sec)	-----	01.92	---	-----	---	---
ExplTime (Sec)	-----	00.24	---	-----	---	---
Lung Age (Yrs)	041	047	115	-----	---	---
FEV6 (L)	03.29	-----	---	-----	---	---
FIF 25% (L/s)	-----	05.94	-----	-----	---	---
FIF 50% (L/s)	-----	06.37	-----	-----	---	---
FIF 75% (L/s)	-----	05.48	-----	-----	---	---
SVC (L)	-----	03.53	---	-----	---	---
ERV (L)	01.33	00.37	028	-----	---	---
IRV (L)	-----	00.47	---	-----	---	---
VE (L/min)	-----	67.00	---	-----	---	---
Rf (l/min)	-----	25.00	---	-----	---	---
Ti (sec)	-----	01.20	---	-----	---	---
Te (sec)	-----	01.20	---	-----	---	---
VT (L)	-----	02.68	---	-----	---	---
VT/Ti	-----	02.23	---	-----	---	---
Ti/Ttot	-----	00.50	---	-----	---	---
IC (L)	-----	03.15	---	-----	---	---
MVV (L/min)	129	133	103	-----	---	---
MRf (l/min)	-----	134.22	---	-----	---	---
MVT (L)	-----	00.99	---	-----	---	---

**Pre Medication Report Indicates
 Mild Obstruction as (FEV1/FVC)%Pred <95 and FVC%Pred >80**



विवेकानन्द आरोग्य केन्द्र



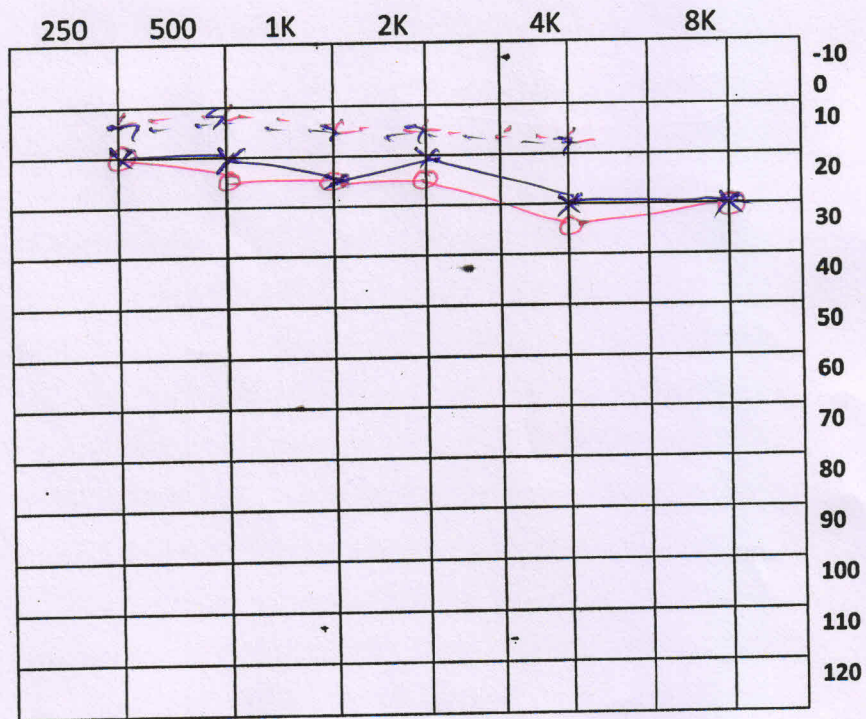
डायलिसिस, डायग्नोस्टिक एवं ओपीडी.
भारत विकास परिषद् महाराणा प्रताप न्यास द्वारा संचालित

Hearing Aids | Hearing Test | Speech Therapy

PURE TONE AUDIOGRAM

Name Arshuman Age/Sex 41y/F Date 1-6-19

Frequency in Hz.



Diagnosis

B/E Hearing with in Normal limit

Signature

VIVEKANAND AROGYA KENDRA

Patient Details **Date:** 01-Jun-19 **Time:** 2:13:58 PM
Name: anshuman ID: 007809
Age: 41 y **Sex:** M **Height:** 66 ins **Weight:** 51 Kgs
Clinical History: nil

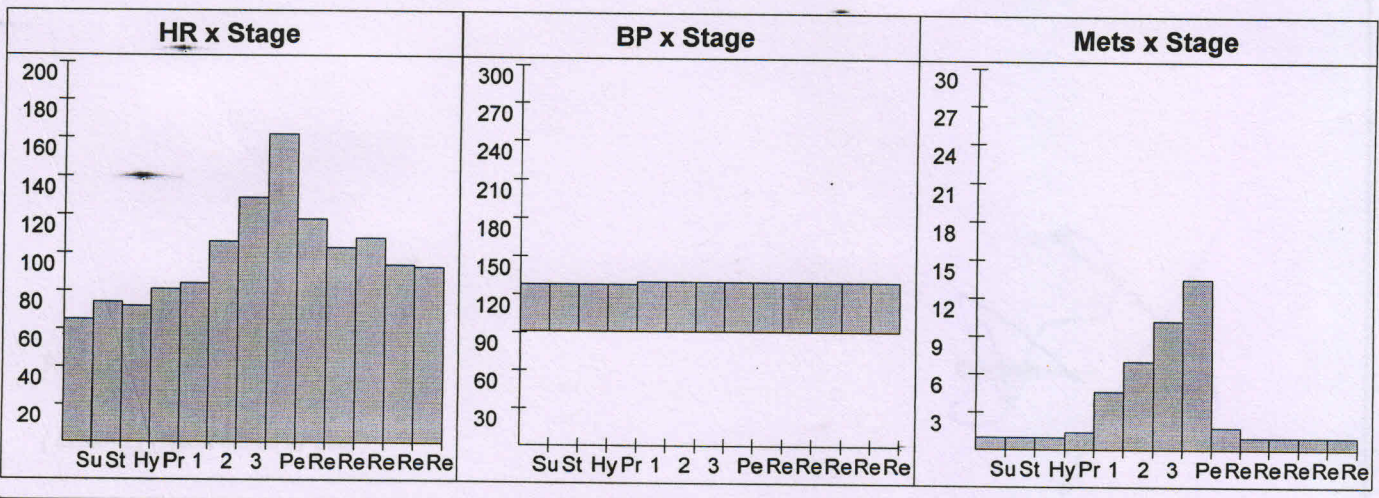
Medications: nil

Test Details

Protocol: Bruce **Pr.MHR:** 179 bpm **THR:** 161 (90 % of Pr.MHR) bpm
Total Exec. Time: 10 m 54 s **Max. HR:** 162 (91% of Pr.MHR) bpm **Max. Mets:** 13.50
Max. BP: 130 / 91 mmHg **Max. BP x HR:** 21060 mmHg/min **Min. BP x HR:** 5915 mmHg/min
Test Termination Criteria: THR achieved

Protocol Details

Stage Name	Stage Time (min : sec)	Mets	Speed (mph)	Grade (%)	Heart Rate (bpm)	Max. BP (mm/Hg)	Max. ST Level (mm)	Max. ST Slope (mV/s)
Supine	0 : 23	1.0	0	0	65	128 / 91	-0.85 aVR	5.31 V3
Standing	0 : 17	1.0	0	0	74	128 / 91	-1.49 aVR	5.31 V3
Hyperventilation	0 : 16	1.0	0	0	72	128 / 91	-1.70 aVR	5.31 V3
1	3 : 0	4.6	1.7	10	84	130 / 91	-1.49 aVR	5.66 V3
2	3 : 0	7.0	2.5	12	106	130 / 91	-1.70 aVR	5.66 V3
3	3 : 0	10.2	3.4	14	129	130 / 91	-2.76 aVR	5.66 V3
Peak Ex	1 : 54	13.5	4.2	16	162	130 / 91	-1.70 aVR	5.66 II
Recovery(1)	1 : 0	1.8	1	0	118	130 / 91	-2.34 aVR	5.66 II
Recovery(2)	1 : 0	1.0	0	0	103	130 / 91	-2.34 aVR	5.66 II
Recovery(3)	1 : 0	1.0	0	0	108	130 / 91	-1.06 aVR	5.66 V3
Recovery(4)	1 : 0	1.0	0	0	94	130 / 91	-0.85 aVR	5.66 V3
Recovery(5)	0 : 36	1.0	0	0	93	130 / 91	-0.42 aVR	3.54 V3



VIVEKANAND AROGYA KENDRA

Patient Details

Date: 01-Jun-19

Time: 2:13:58 PM

Name: anshuman ID: 007809

Age: 41 y

Sex: M

Height: 66 ins

Weight: 51 Kgs

Interpretation

During stress testing, No significant ST-T changes and symptoms seen, no stress induced myocardial ischemic changes seen.
Please correlate clinically.

Ref. Doctor: -----

(Summary Report edited by user)

Doctor: -----

Dr. ARUN KUMAR GARG
MBS, PGDCC, FNIC, FICC
Consultant Cardiology
Vivekanand Arogya Kendra
Reg. No. HMC-8027