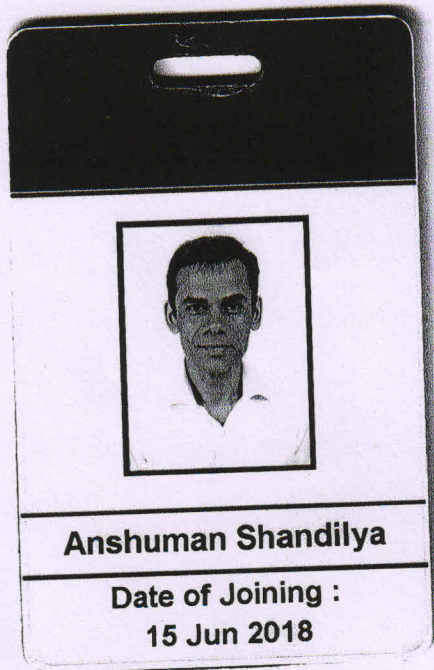



सत्यमेव जयते  
भारत सरकार



आधार

भारतीय विशिष्ट पहचान प्राधिकरण

भारत सरकार

Unique Identification Authority of India

Government of India

नामांकन क्रम / Enrollment No.: 1218/23357/02922

To

ऋचा शंदिन्या

Richa Shandilya

W/O: Anshuman Shandilya

House No- 1177 First Floor

Sector - 4 Urban Estate , Gurgaon

Gurgaon

Gurgaon

Farrukhnagar Gurgaon

Haryana 122001

9899335503

04/09/2013

71864806



MN718648069FT



आपका आधार क्रमांक / Your Aadhaar No. :

**6559 3973 7969**

आधार - आम आदमी का अधिकार



भारत सरकार

Government of India



ऋचा शंदिन्या

Richa Shandilya

जन्म तिथि / DOB : 14/07/1980

महिला / Female



**6559 3973 7969**

आधार - आम आदमी का अधिकार


## CERTIFICATE OF MEDICAL FITNESS

This is to certify that I have conducted the clinical examination

of Riche on \_\_\_\_\_

After reviewing the medical history and on clinical examination it has been found that he/she is

	Tick
<ul style="list-style-type: none"> <li>• Medically Fit</li> </ul>	<input type="checkbox"/>
<ul style="list-style-type: none"> <li>• Fit with restrictions/recommendations</li> </ul> <p>Though following restrictions have been revealed, in my opinion, these are not impediments to the job.</p> <p>1..... <u>Dyslipidemia</u> .....</p> <p>2..... <u>Hydro nephrosis Rt Kidney</u> .....</p> <p>3.....</p> <p>However the employee should follow the advice/medication that has been communicated to him/her.</p> <p>Review after <u>3 m.</u></p>	<input type="checkbox"/>
<ul style="list-style-type: none"> <li>• Currently Unfit.</li> </ul> <p>Review after _____ recommended</p>	<input type="checkbox"/>
<ul style="list-style-type: none"> <li>• Unfit</li> </ul>	<input type="checkbox"/>

Dr.   
 Medical Officer  
 The Apollo Clinic, (Location)

**DR. ASHOK K. GUPTA**  
 MBBS, MD  
 Consulting Physician  
 Regd. No. 7513 (HMC)

*This certificate is not meant for medico-legal purposes*

## उपलब्ध ओ.पी.डी. सुविधाएँ

- हृदय रोग चिकित्सा  
(Cardiology)
- बाल एवं भ्रूण रोग चिकित्सा  
(Paediatrics & Fetal Medicine)
- बाल रोग चिकित्सा  
(Paediatrics)
- स्त्री रोग चिकित्सा  
(Gynaecology)
- हड्डी रोग चिकित्सा  
(Orthopaedics)
- दन्त चिकित्सा  
(Dental Care)
- सामान्य चिकित्सा  
(General Physician)
- फिजियोथैरेपी  
(Physiotherapy)
- चर्म रोग चिकित्सा  
(Dermatology)
- मूत्र रोग चिकित्सा  
(Urology)
- गुर्दा रोग चिकित्सा  
(Nephrology)

## उपलब्ध जाँच

- डायलिसिस (Dialysis)
- अल्ट्रासाउण्ड (Ultrasound)
- ईको (Echo)
- स्ट्रेस ईको (Stress Echo)
- टी.एम.टी. (T.M.T.)
- पी.एफ.टी. (Lung Function Test)
- ई.सी.जी. (E.C.G.)
- ई.ई.जी. (E.E.G.)
- एक्स-रे (X-Ray)
- मैमोग्राफी (Mammography)
- ओ.पी.जी. (Dental X-Ray)
- हॉल्टर टेस्ट (Holter Test)

Ref. No.:.....

Date:.....

<b>Name of patient:</b> Mrs. RICHA	<b>Age:</b> 38	<b>M/F:</b> F
<b>Consultant:</b>	<b>Speciality:</b> Package	
<b>MR No :</b> MR007810	<b>Visit No:</b> OP016355	<b>Date:</b> 01-06-2019

HT = 5' 2"  
WT = 53.5 kg  
PR = 74 bpm  
Pb = 120/70 mm Hg  
CVS  
Abd | ST  
Chest

Not for Medico Legal Purpose

खून एवं मल-मूत्र की जाँच NABL द्वारा मान्यता प्राप्त MolQ लैब द्वारा की जाती है।

सम्पर्क सूत्र: 0124-2224102 / 103 / 104 | Mob.: 8683061905, 8683061906

ओ.पी.डी. पर्ची का शुल्क केवल तीन दिन के लिए मान्य रहेगा।

## उपलब्ध ओ.पी.डी. सुविधाएँ

- हृदय रोग चिकित्सा  
(Cardiology)
- बाल एवं भ्रूण रोग चिकित्सा  
(Paediatrics & Fetal Medicine)
- बाल रोग चिकित्सा  
(Paediatrics)
- स्त्री रोग चिकित्सा  
(Gynaecology)
- हड्डी रोग चिकित्सा  
(Orthopaedics)
- दन्त चिकित्सा  
(Dental Care)
- सामान्य चिकित्सा  
(General Physician)
- फिजियोथैरेपी  
(Physiotherapy)
- चर्म रोग चिकित्सा  
(Dermatology)
- मूत्र रोग चिकित्सा  
(Urology)
- गुर्दा रोग चिकित्सा  
(Nephrology)

## उपलब्ध जाँच

- डायलिसिस (Dialysis)
- अल्ट्रासाउण्ड (Ultrasound)
- ईको (Echo)
- स्ट्रेस ईको (Stress Echo)
- टी.एम.टी. (T.M.T.)
- पी.एफ.टी. (Lung Function Test)
- ई.सी.जी. (E.C.G.)
- ई.ई.जी. (E.E.G.)
- एक्स-रे (X-Ray)
- मैमोग्राफी (Mammography)
- ओ.पी.जी. (Dental X-Ray)
- हॉल्टर टेस्ट (Holter Test)

Ref. No.:.....

Date:.....

Name of patient: Mrs. RICHA	Age: 38	M/F: F
Consultant:	Speciality: Package	
MR No : MR007810	Visit No: OP016355	Date: 01-06-2019

for Routine checkup.  
no gynaec prob  
3-4  
25- net well person.  
Cap. Antoxia - bc  
00X1ml  
net well  
for P/S & P/V  
Pap Smear: examine  
& refer for Pap smear  
Adv  
P

Not for Medico Legal Purpose

खून एवं मल-मूत्र की जाँच NABL द्वारा मान्यता प्राप्त MoIQ लैब द्वारा की जाती है।

सम्पर्क सूत्र: 0124-2224102 / 103 / 104 | Mob.: 8683061905, 8683061906

ओ.पी.डी. पर्ची का शुल्क केवल तीन दिन के लिए मान्य रहेगा।

## Radiology Report

Name : Mrs. RICHA  
Age/Gender : 38 Y/F  
Prescribed Doctor : Self

MR No : MR007810  
Visit ID : OP016355  
Report Date : 01-06-2019 09:51

## Ultrasound

### USG EXAMINATION : WHOLE ABDOMEN

**Liver** shows normal shape and size with homogenous echo texture. Intrahepatic biliary radicals are not dilated. No focal lesion is seen. **Portal Vein** shows normal calibre.

**Gall bladder** shows physiological distension and normal wall thickness. No calculus or mass is seen in the lumen.

**CBD** is normal in diameter. No calculus is seen

**Pancreas** is normal in size, shape and echo texture.

**Spleen** is normal in shape, size and echo texture.

**Right kidney** show normal shape & size. Cortico-medullary differentiation is maintained. **Right kidney shows mild dilatation of right sided pelvi-calyceal system. (AP dimension of pelvis is approx. 15mm).**

Right kidney show no calculus or hydronephrosis. Right kidney measures 112 x 46mm.

**Left kidney** show normal shape & size. Cortico-medullary differentiation is maintained. Left kidney show no calculus or hydronephrosis. Left kidney measures 108 x 40mm.

No free fluid is seen in the intra-peritoneal cavity. No evidence of mesenteric lymphadenopathy is seen.

**Urinary** bladder is normal shape and size with normal wall thickness. No mass or calculus is seen.

**Uterus** shows normal shape, size and echo texture. No focal lesion is seen. Uterus measures 72 x 42 x 35mm. Endometrial thickness is 6.2 mm.

**Both Ovaries** are normal in size, shape and echotexture.

Right ovary measures 21 x 15mm.


Left ovary measures 24 x 20mm.

**Bilateral adnexae** are clear.

**Cul-de-sac** is clear.

**Impression:- Right kidney shows mild dilatation of right sided pelvi-calyceal system.**

**Adv:- Clinical correlation and further evaluation to rule out possibility of any ureteric obstruction (like PUJ Obstruction).**

  
Dr. Pawan Joon  
MD ( Radio- diagnosis)

## Radiology Report

Name : Mrs. RICHA  
Age/Gender : 38 Y/F  
Prescribed Doctor : Self

MR No : MR007810  
Visit ID : OP016355  
Report Date : 03-06-2019 13:41

## X-Ray

### X-RAY CHEST PA VIEW

*Rotated radiograph.*

Bilateral lung fields appears to be clear. No obvious pulmonary parenchymal lesion is seen.


Trachea is central.

Cardiac configuration appears to be normal with normal cardio-thoracic ratio.

Both costo phrenic angles and domes of diaphragm are normal.

Visualized soft tissue and bony thoracic cage appears to be normal.

PLEASE CORRELATE CLINICALLY.

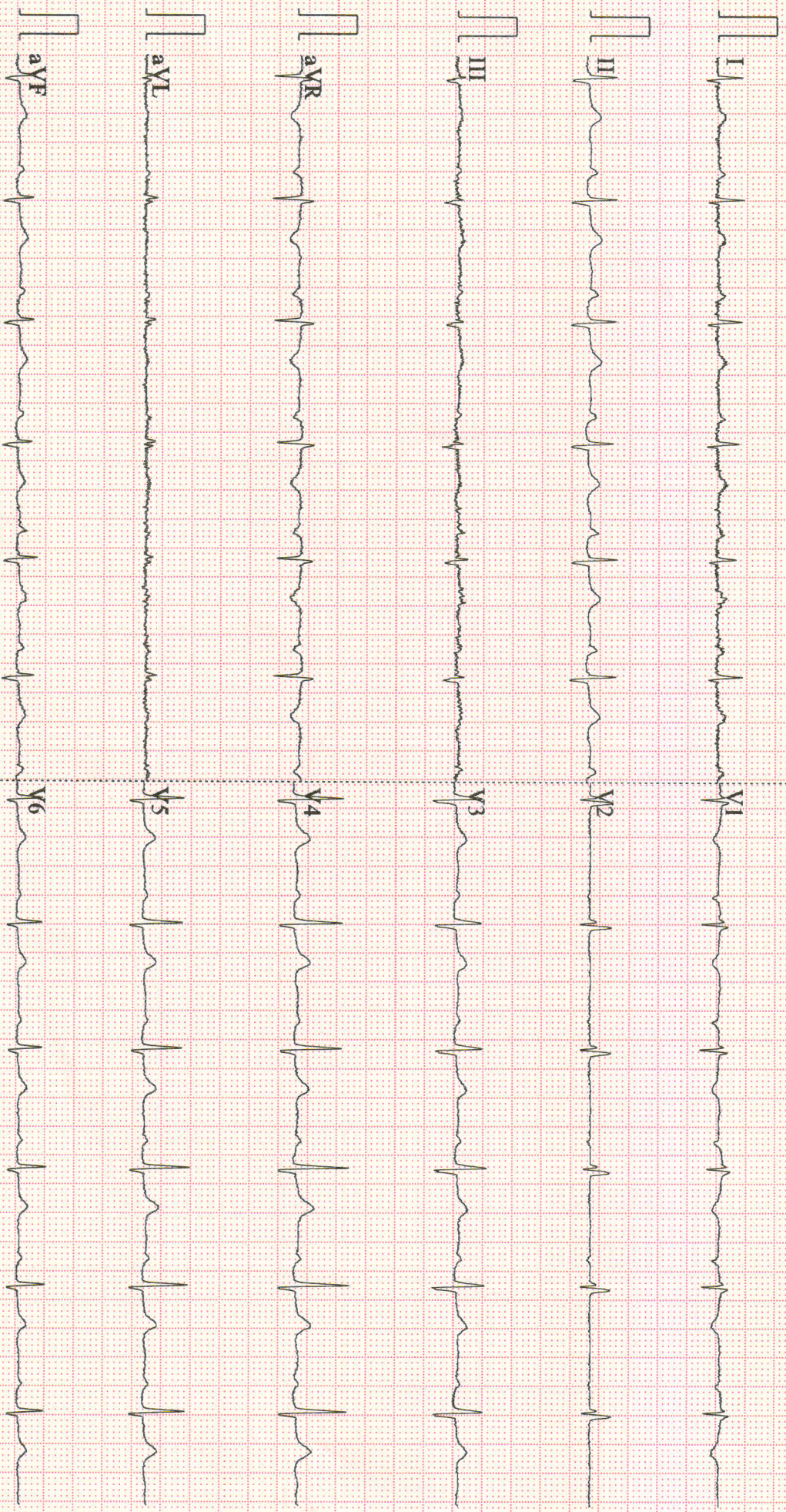
  
DR. PAWAN JOON  
MD (Radio-diagnosis)

richa  
Female 38Y ears

HR	:	71	bpm
P	:	85	ms
PR	:	194	ms
QRS	:	76	ms
QT/QTc	:	401/438	ms
P/QRS/T	:	49/13/51	°
RV5/SV1	:	0.725/0.312	mV

Diagnosis Information:  
Sinus Rhythm  
Larged P/rV1

Report Confirmed by:





# VIVEKANAND AROGYA KENDRA

**Patient Details**

Name: Richa ID: 007810

Age: 38 y

Clinical History: NIL

Date: 01-Jun-19

Sex: F

Time: 2:46:15 PM

Height: 62 ins

Weight: 53 Kgs

**Medications:** NIL

**Test Details**
**Protocol:** Bruce

**Total Exec. Time:** 7 m 29 s

**Max. BP:** 137 / 87 mmHg

**Test Termination Criteria:** THR achieved

**Pr.MHR:** 182 bpm

**Max. HR:** 163 ( 90% of Pr.MHR )bpm

**Max. BP x HR:** 22331 mmHg/min

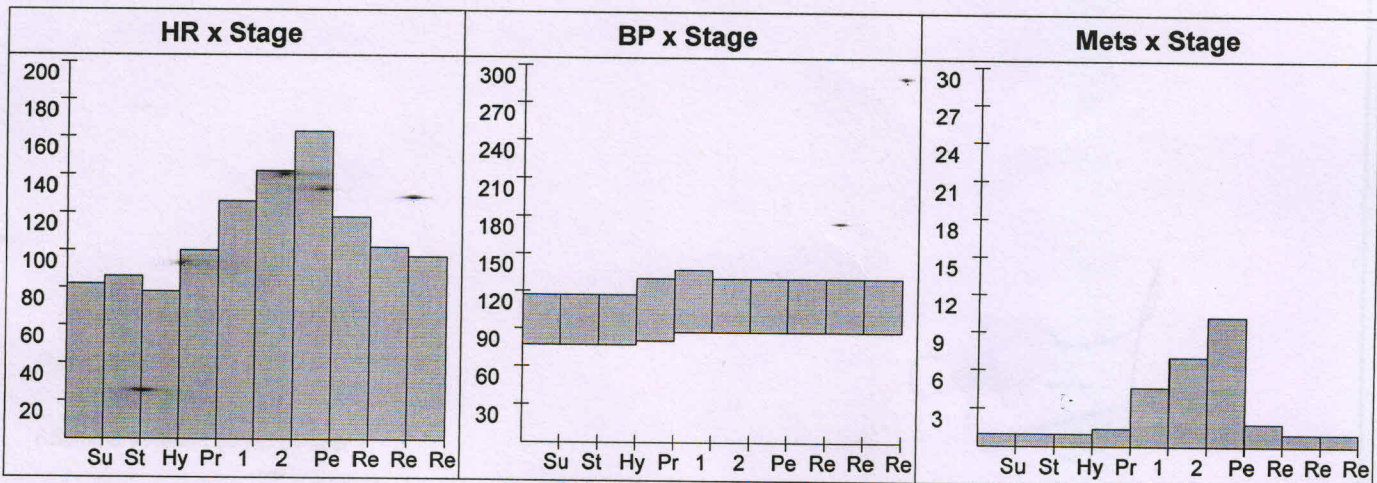
**THR:** 163 (90 % of Pr.MHR) bpm

**Max. Mets:** 10.20

**Min. BP x HR:** 6006 mmHg/min

**Protocol Details**

Stage Name	Stage Time (min : sec)	Mets	Speed (mph)	Grade (%)	Heart Rate (bpm)	Max. BP (mm/Hg)	Max. ST Level (mm)	Max. ST Slope (mV/s)
Supine	0 : 18	1.0	0	0	82	117 / 77	-0.64 III	0.71 I
Standing	0 : 11	1.0	0	0	86	117 / 77	-0.42 III	0.71 I
Hyperventilation	0 : 54	1.0	0	0	78	117 / 77	-0.85 III	1.42 V2
1	3 : 0	4.6	1.7	10	126	137 / 87	-0.85 III	2.48 I
2	3 : 0	7.0	2.5	12	142	130 / 87	-0.85 III	3.18 I
Peak Ex	1 : 29	10.2	3.4	14	163	130 / 87	-1.06 III	3.18 I
Recovery(1)	1 : 0	1.8	1	0	118	130 / 87	-1.70 III	3.54 I
Recovery(2)	1 : 0	1.0	0	0	102	130 / 87	-1.27 III	2.83 I
Recovery(3)	0 : 57	1.0	0	0	97	130 / 87	-0.64 V3	1.06 I



# VIVEKANAND AROGYA KENDRA

## Patient Details

Date: 01-Jun-19

Time: 2:46:15 PM

Name: Richa ID: 007810

Age: 38 y

Sex: F

Height: 62 ins

Weight: 53 Kgs

## Interpretation\*

During stress testing, no significant ST-T changes seen and no symptoms seen, no stress induced reversible myocardial ischemic changes seen.  
Please correlate clinically.

Ref. Doctor: -----

Doctor: -----

( Summary Report edited by user )