

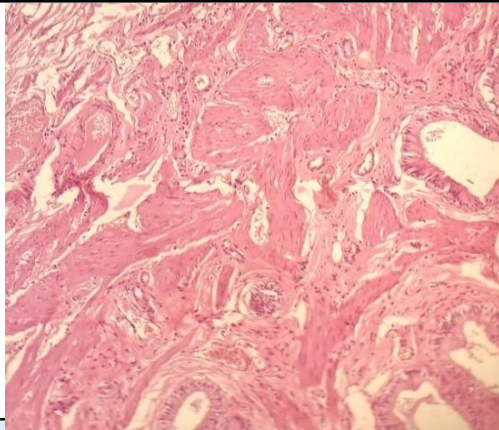
Patient Name	Mrs. SUNHERI	Client Name	Chiranjeev Path Lab	Specimen Received	29/05/19
Age/Sex	27 Years/Female	Client Code	MOLQ1019P	Specimen Type	Tissue
Patient ID	011905290103	Ref. Doctor		Collection Date	29/05/19
Specimen ID	MOLQ/B-1008/19			Report Date	03/06/19

SURGICAL PATHOLOGY REPORT

Gall bladder

DIAGNOSIS

CHOLECYSTITIS WITH CHOLELITHIASIS



SPECIMEN
Gall bladder

GROSS

Received 5x2.5cm long gallbladder with tiny stones.

Microscopy

Section examined shows ulcerative mucosa and Rokitansky-Aschoff sinuses (irregularly shaped tubular structures lined by cuboidal lining epithelium with round to oval nucleus) with fibrocollagenous tissue and inflammatory cells (lymphocytes).

Note : All biopsy specimen will be stored for 15 (fifteen) days, block and slides for 5 (five) years only from the time of receipt at the laboratory. No request, for any of the above, will be entertained after the due date.

Reference

- i) Rosai and Ackerman's Surgical Pathology.
- ii) Modern Surgical Pathology.

Gulshan Yadav, MD
Consultant Pathologist