

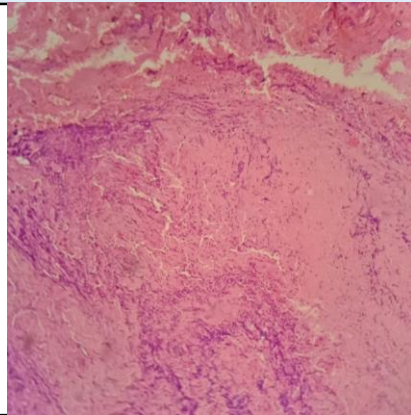
Patient Name	Mrs. FATIMA 9231	Client Name	Patients Care Clinical	Specimen Received	27/05/2019
Age/Sex	50 Years/Female		Laboratory, Jammu & Kashmir	Specimen Type	Tissue
Patient ID	011905270215	Client Code	MolQ1839P	Collection Date	27/05/2019
Specimen ID	MOLQ/B-989/19	Ref. Doctor	LIFE CARE DOORU	Report Date	03/06/2019

SURGICAL PATHOLOGY REPORT

Hernia

DIAGNOSIS

Hernial sac with non specific inflammation.



SPECIMEN

Hernia

GROSS

Received two greyish white tissue piece measuring 7x6,6x4cm .

Microscopy

Section examined shows fibro collagenous tissue , blood vessel mononuclear inflammatory cells.

No granuloma and no malignant cells seen.

Section also shows mature adipose cells with lymphoid follicle.

Note : All biopsy specimen will be stored for 15 (fifteen)days, block and slides for 5(five) years only from the time of receipt at the laboratory. No request ,for any of the above ,will be entertained after the due date.

Reference

- i) Rosai and Ackerman's Surgical Pathology.
- ii) Modern Surgical Pathology.

Gulshan Yadav, MD
Consultant Pathologist