

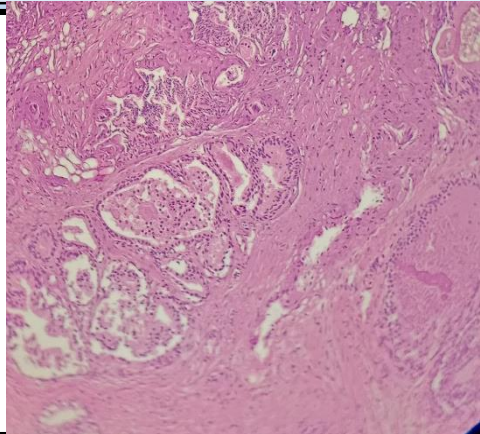
Patient Name	Mr. KALU RAM 31917	Client Name	Pushpanjali Hospital	Specimen Received	31/05/19
Age/Sex	60 Years/Male	(Rewari)		Specimen Type	Tissue
Patient ID	011905310294	Client Code	MolQ1789CM	Collection Date	31/05/19
Specimen ID	MOLQ/B-1023/19	Ref. Doctor	DR.RACHNA	Report Date	03/06/19

SURGICAL PATHOLOGY REPORT

TURP chips

DIAGNOSIS

BENIGN PROSTATIC HYPERPLASIA



SPECIMEN

TURP chips

GROSS

Received multiple greyish white tissue piece 4x3cm in aggregate.

Microscopy

Section examined shows bilayered prostatic glands with columnar lining epithelium and with small round to oval nucleus surrounded by large number of fibrocollagenous tissue and mononuclear inflammatory cell.

Note : All biopsy specimen will be stored for 15 (fifteen)days, block and slides for 5(five) years only from the time of receipt at the laboratory. No request ,for any of the above ,will be entertained after the due date.

Reference

- i) Rosai and Ackerman's Surgical Pathology.
- ii) Modern Surgical Pathology.

Gulshan Yadav, MD
Consultant Pathologist