

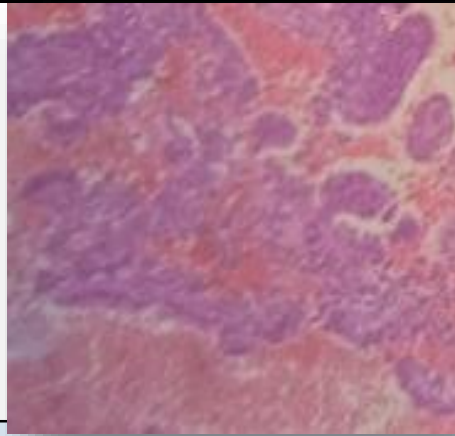
Patient Name	Ms. KRISHNA 32012	Client Name	Pushpanjali Hospital	Specimen Received	31/05/19
Age/Sex	48 Years/Female	(Rewari)		Specimen Type	Tissue
Patient ID	011905310282	Client Code	MolQ1789CM	Collection Date	31/05/19
Specimen ID	MOLQ/B-1021/19	Ref. Doctor	DR.RACHNA	Report Date	03/06/19

SURGICAL PATHOLOGY REPORT

Endometrium

DIAGNOSIS

Disordered proliferative phase.



SPECIMEN

Endometrium

GROSS

Received multiple greyish white tissue piece.


Microscopy

Section examined shows small endometrial glands with round nucleus with tortuous endometrial glands having columnar lining epithelium with stroma shows mononuclear inflammatory cells. No granuloma no malignant cells seen.

Note : All biopsy specimen will be stored for 15 (fifteen) days, block and slides for 5 (five) years only from the time of receipt at the laboratory. No request, for any of the above, will be entertained after the due date.

Reference

- i) Rosai and Ackerman's Surgical Pathology.
- ii) Modern Surgical Pathology.


Gulshan Yadav, MD
Consultant Pathologist