

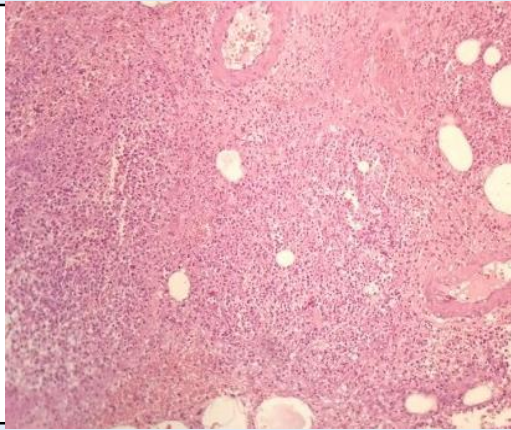
Patient Name	Master. AQIL JAVEED	Client Name	Apollo Laboratories CC, Jammu & Kashmir	Specimen Received	31/05/19
415 SOGAM		Client Code	MolQ1961P	Specimen Type	Tissue
Age/Sex	12 Years/Male	Ref. Doctor	PROF G M SHEIKH	Collection Date	31/05/19
Patient ID	011905310189			Report Date	03/06/19
Specimen ID	MOLQ/B-1027/19				

SURGICAL PATHOLOGY REPORT

Appendix

DIAGNOSIS

ACUTE APPENDICITIS



SPECIMEN

Appendix

GROSS

Received 6x1.1cm long appendix cut section shows fecolith.

Microscopy

Section examined shows lymphoid follicles with ulcerative mucosa. Deeper tissue shows inflammatory cells (polymorphs, lymphocytes and few histiocytes).

Note : All biopsy specimen will be stored for 15 (fifteen)days, block and slides for 5(five) years only from the time of receipt at the laboratory. No request ,for any of the above ,will be entertained after the due date.

Reference

- i) Rosai and Ackerman's Surgical Pathology.
- ii) Modern Surgical Pathology.

Gulshan Yadav, MD
Consultant Pathologist