

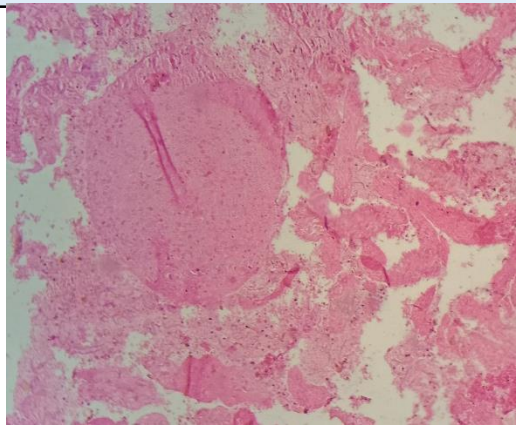
<b>Patient Name</b>	<b>Ms. SARITA W/O AJE</b>	<b>Client Name</b>	Lalita Memorial Hospital Pvt. Ltd.	<b>Specimen Received</b>	28/05/2019
<b>Age/Sex</b>	27 Years/Female	(Rewari)		<b>Specimen Type</b>	Tissue
<b>Patient ID</b>	011905280316	<b>Client Code</b>	MolQ1652P	<b>Collection Date</b>	28/05/2019
<b>Specimen ID</b>	MOLQ/B-1002/19	<b>Ref. Doctor</b>		<b>Report Date</b>	03/06/2019

## SURGICAL PATHOLOGY REPORT

### Endometrium

#### DIAGNOSIS

**Proliferative phase.**



#### **SPECIMEN**

Endometrium

#### **GROSS**

Received multiple greyish white tissue piece.

#### **Microscopy**

Section examined shows only few endometrial glands with lining epithelium with small round nucleus with large number of RBCs and scanty stromal cells.

**Note :** All biopsy specimen will be stored for 15 (fifteen)days, block and slides for 5(five) years only from the time of receipt at the laboratory. No request ,for any of the above ,will be entertained after the due date.

#### **Reference**

- i) Rosai and Ackerman's Surgical Pathology.
- ii) Modern Surgical Pathology.

**Gulshan Yadav, MD**  
Consultant Pathologist