

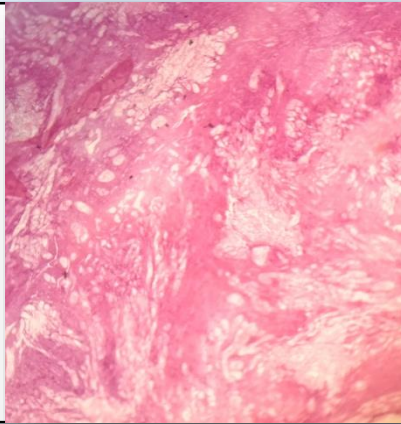
Patient Name	Mrs. HARSHITA	Client Name	Sona Devi Hospital	Specimen Received	28/05/2019
Age/Sex	22 Years/Female	Client Code	MolQ1233P	Specimen Type	Tissue
Patient ID	011905280037	Ref. Doctor		Collection Date	28/05/2019
Specimen ID	MOLQ/B-1000/19			Report Date	03/06/2019

SURGICAL PATHOLOGY REPORT

Right breast fibroadenoma

DIAGNOSIS

FIBROADENOMA



SPECIMEN

Right breast fibroadenoma

GROSS

Received two greyish white tissue piece 4x2.1, 2.1x2cm .

Microscopy

Section examined shows ducts with cuboidal epithelium with small round nucleus surrounded by fibrocollagenous tissue.

No granuloma seen. No malignant cells seen.

Note : All biopsy specimen will be stored for 15 (fifteen) days, block and slides for 5 (five) years only from the time of receipt at the laboratory. No request ,for any of the above ,will be entertained after the due date.

Reference

- i) Rosai and Ackerman's Surgical Pathology.
- ii) Modern Surgical Pathology.

Gulshan Yadav, MD
Consultant Pathologist