

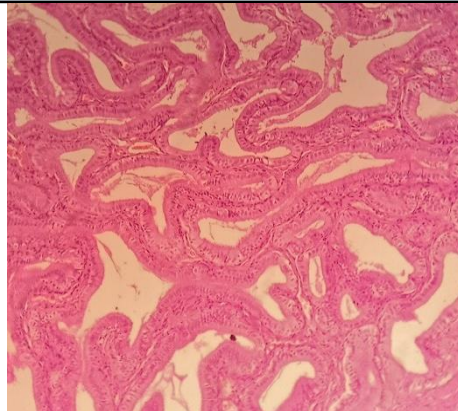
Patient Name	FARUK	Client Name	Murad Hospital, Nuh	Specimen Received	27/05/2019
Age/Sex	60 YRS/M	Client Code		Specimen Type	Tissue
Patient ID	011905270280	Ref. Doctor		Collection Date	27/05/2019
Specimen ID	MOLQ/B-979/19			Report Date	03/06/2019

SURGICAL PATHOLOGY REPORT

Gall bladder

DIAGNOSIS

CHOLECYSTITIS WITH CHOLELITHIASIS



SPECIMEN

Gall bladder

GROSS

Received 7x3cm long gall bladder cut section shows stones.

Microscopy

Section examined shows ulcerative mucosa and Rokitansky-Aschoff sinuses (irregularly shaped tubular structures lined by cuboidal lining epithelium with round to oval nucleus) with fibro collagenous tissue and inflammatory cells (lymphocytes).

Note : All biopsy specimen will be stored for 15 (fifteen) days, block and slides for 5 (five) years only from the time of receipt at the laboratory. No request, for any of the above, will be entertained after the due date.

Reference

- i) Rosai and Ackerman's Surgical Pathology.
- ii) Modern Surgical Pathology.

Gulshan Yadav, MD
Consultant Pathologist