

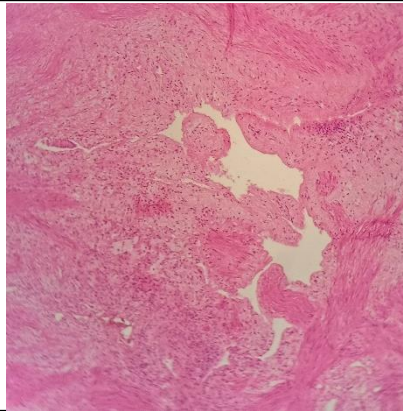
Patient Name	Mrs. RAFEEQA 9226	Patient Name	Patients Care Clinical	Specimen Received	27/05/2019
Age/Sex	50 Years/Female		Laboratory, Jammu & Kashmir	Specimen Type	Tissue
Patient ID	011905270210	Client Code	MolQ1839P	Collection Date	27/05/2019
Specimen ID	MOLQ/B-988/19	Ref. Doctor	LIFE CARE DOORU	Report Date	03/06/2019

SURGICAL PATHOLOGY REPORT

Gall bladder

DIAGNOSIS

CHOLECYSTITIS WITH CHOLELITHIASIS



SPECIMEN

Gall bladder

GROSS

Received 6x3cm long gall bladder cut section shows stones.

Microscopy

Section examined shows ulcerative mucosa and rokitansky aschoff sinus (irregularly shaped tubular structures lined by cuboidal lining epithelium with round to oval nucleus) with fibro collagenous tissue and inflammatory cells (lymphocytes).

Note : All biopsy specimen will be stored for 15 (fifteen)days, block and slides for 5(five) years only from the time of receipt at the laboratory. No request ,for any of the above ,will be entertained after the due date.

Reference

- i) Rosai and Ackerman's Surgical Pathology.
- ii) Modern Surgical Pathology.

Gulshan Yadav, MD
Consultant Pathologist