

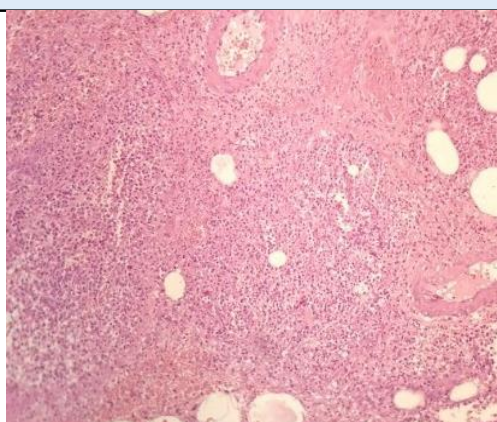
<b>Patient Name</b>	Master. AVIKANT	<b>Client Name</b>	Chetanya Hospital	<b>Specimen Received</b>	27/05/19
<b>Age/Sex</b>	10 YRS/M			<b>Specimen Type</b>	Tissue
<b>Patient ID</b>	011905270020			<b>Collection</b>	27/05/19
<b>Specimen ID</b>	MOLQ/B-978/19			<b>Report Date</b>	03/06/19

## SURGICAL PATHOLOGY REPORT

### Appendix

#### DIAGNOSIS

#### ACUTE APPENDICITIS



#### SPECIMEN

Appendix

#### GROSS

Received 4.2x1.6cm long appendix cut section shows fecolith.

#### Microscopy

Section examined shows lymphoid follicles with ulcerative mucosa. Deeper tissue shows inflammatory cells (polymorphs, lymphocytes and few histiocytes).

**Note :** All biopsy specimen will be stored for 15 (fifteen)days, block and slides for 5(five) years only from the time of receipt at the laboratory. No request ,for any of the above ,will be entertained after the due date.

#### Reference

- i) Rosai and Ackerman's Surgical Pathology.
- ii) Modern Surgical Pathology.

**Gulshan Yadav, MD**  
Consultant Pathologist