

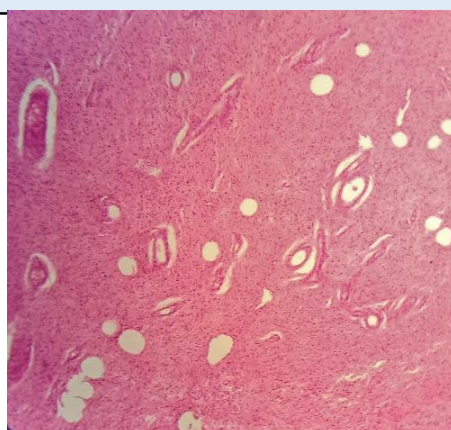
Patient Name	Mrs. KHALIDA 9109	Client Name	Patients Care Clinical	Specimen Received	17/05/19
Age/Sex	55 YRS/F		Laboratory, Jammu & Kashmir	Specimen Type	Tissue
Patient ID	011905150424			Collection	17/05/19
Specimen ID	MOLQ/B-978/19			Report Date	03/06/19

SURGICAL PATHOLOGY REPORT

Thigh swelling

DIAGNOSIS

Benign mesenchymal lesion.



SPECIMEN

Thigh swelling

GROSS

Received 3x2cm greyish white tissue piece with 2x2cm with skin growth.

Microscopy

Section examined shows Squamous lining epithelium having round nucleus with hyperkeratosis and parakeratosis. Deeper tissue shows fibro collagenous tissue, blood vessels, inflammatory cells(lymphocyte, polymorphs) mature adipose cells. No granuloma and no malignant cells seen.

Note : All biopsy specimen will be stored for 15 (fifteen)days, block and slides for 5(five) years only from the time of receipt at the laboratory. No request ,for any of the above ,will be entertained after the due date.

Reference

- i) Rosai and Ackerman's Surgical Pathology.
- ii) Modern Surgical Pathology.

Gulshan Yadav, MD
Consultant Pathologist