

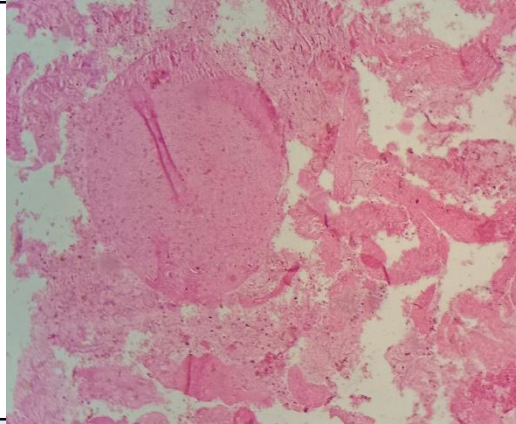
Patient Name	Ms. RUNA	Client Name	Civil Hospital Sec-10	Specimen Received	21/05/19
Age/Sex	32 YRS/F	Client Code		Specimen Type	Tissue
Patient ID	011905210359	Ref. Doctor		Collection Date	21/05/19
Specimen ID	MOLQ/B-924/19			Report Date	30/05/19

SURGICAL PATHOLOGY REPORT

Endometrium

DIAGNOSIS

Kindly Co-relate clinically and radiologically.
As Section shows degenerative autolytic changes.



SPECIMEN

Endometrium

GROSS

Received multiple greyish white tissue piece.


Microscopy

Section examined shows few broken endometrial glands fibrin with large number of RBCs, hemosiderin laden, macrophages and degenerative cells (autolytic changes).

Note : All biopsy specimen will be stored for 15 (fifteen)days, block and slides for 5(five) years only from the time of receipt at the laboratory. No request ,for any of the above ,will be entertained after the due date.

Reference

- i) Rosai and Ackerman's Surgical Pathology.
- ii) Modern Surgical Pathology.


Gulshan Yadav, MD
Consultant Pathologist