

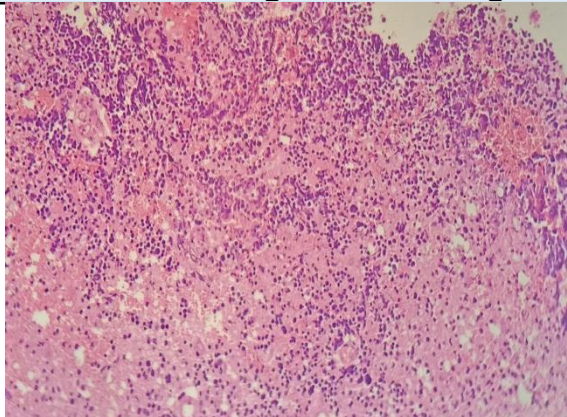
Patient Name	Mr. KRISHAN LAL	Client Name	Malhotra Diagnostics	Specimen Received	21/05/19
Age/Sex	72 YRS/M	Client Code		Specimen Type	Tissue
Patient ID	011905210312	Ref. Doctor		Collection Date	21/05/19
Specimen ID	MOLQ/B-925/19			Report Date	31/05/19

SURGICAL PATHOLOGY REPORT

Left parietal periventricular cystic mass.

DIAGNOSIS

**Suggestive of Papillary Ependymoma:WHO grade II.
Please Correlate clinically/IHC study.**



SPECIMEN

Left parietal periventricular cystic mass.

GROSS

Received multiple greyish white tissue piece.

Microscopy

Section examined shows malignant tumor showing papillae like architecture with fibrovascular core and pseudostratified cuboidal epithelium.

Tumor cells are small, show moderate nuclear pleomorphism with salt and paper nuclear chromatin and hyperchromasia. Pseudorosettes are seen. Glial tissue with crush artifacts are seen.

Note : All biopsy specimen will be stored for 15 (fifteen)days, block and slides for 5(five) years only from the time of receipt at the laboratory. No request ,for any of the above ,will be entertained after the due date.

Reference

- i) Rosai and Ackerman's Surgical Pathology.
- ii) Modern Surgical Pathology.

**Gulshan Yadav, MD
Consultant Pathologist**