

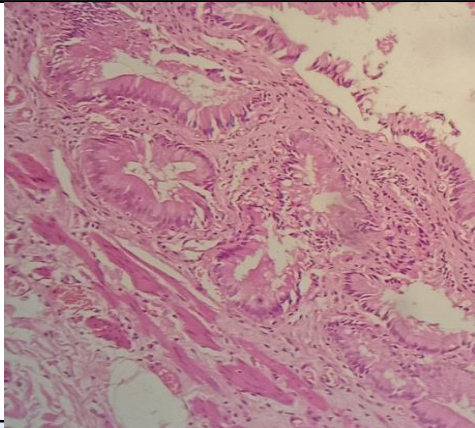
Patient Name	PAYAL RANI	Client Name	MolQ Collection Centre CSK	Specimen Received	26/05/19
Age/Sex	25 YRS/F		Hospital, Sohna	Specimen Type	Tissue
Patient ID	011905260180	Client Code		Collection Date	26/05/19
Specimen ID	MOLQ/B-975/19	Ref. Doctor		Report Date	29/05/19

SURGICAL PATHOLOGY REPORT

Gallbladder

DIAGNOSIS

CHOLECYSTITIS WITH CHOLELITHIASIS



SPECIMEN

Gallbladder

GROSS

Received 9x3cm long gallbladder cut section shows multiple stones.

Microscopy

Section examined shows ulcerative mucosa and Rokitansky-Aschoff sinuses (irregularly shaped tubular structures lined by cuboidal lining epithelium with round to oval nucleus) with fibro collagenous tissue and inflammatory cells (lymphocytes).

Note : All biopsy specimen will be stored for 15 (fifteen) days, block and slides for 5 (five) years only from the time of receipt at the laboratory. No request, for any of the above, will be entertained after the due date.

Reference

- i) Rosai and Ackerman's Surgical Pathology.
- ii) Modern Surgical Pathology.

**Gulshan Yadav, MD
Consultant Pathologist**