

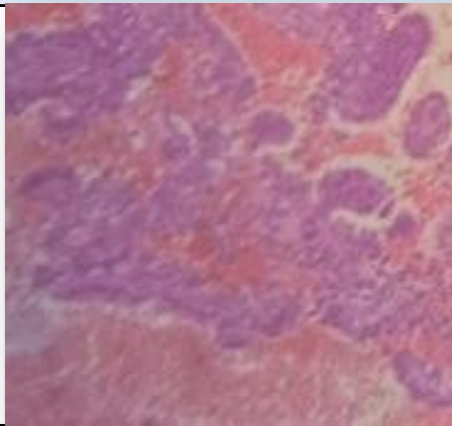
<b>Patient Name</b>	<b>Ms. SUNITA 31670</b>	<b>Client Name</b>	Pushpanjali Hospital	<b>Specimen Received</b>	25/05/19
<b>Age/Sex</b>	44 Years/Female	(Rewari)		<b>Specimen Type</b>	Tissue
<b>Patient ID</b>	011905250334	<b>Client Code</b>	MolQ1789CM	<b>Collection Date</b>	25/05/19
<b>Specimen ID</b>	MOLQ/B-968/19	<b>Ref. Doctor</b>	DR.RACHNA	<b>Report Date</b>	29/05/19

## SURGICAL PATHOLOGY REPORT

### Endometrium

#### DIAGNOSIS

**Disordered Proliferative Phase.**



#### **SPECIMEN**

Endometrium

#### **GROSS**

Received multiple greyish white tissue piece.

#### **Microscopy**

Section examined shows small and tortuous endometrial glands having columnar to cuboidal lining epithelium with small round nucleus stroma shows mononuclear inflammatory cells. No granuloma and no malignant cells seen.

**Note :** All biopsy specimen will be stored for 15 (fifteen) days, block and slides for 5 (five) years only from the time of receipt at the laboratory. No request, for any of the above, will be entertained after the due date.

#### **Reference**

- i) Rosai and Ackerman's Surgical Pathology.
- ii) Modern Surgical Pathology.

**Gulshan Yadav, MD**  
Consultant Pathologist