

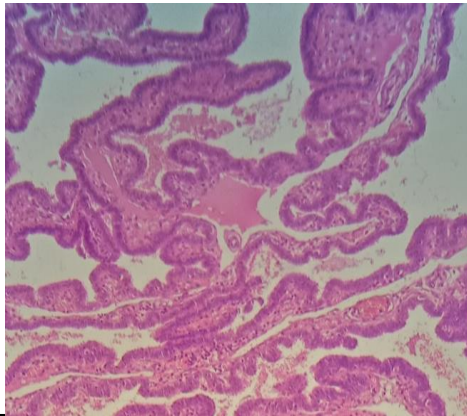
<b>Patient Name</b>	AMEERA/HAJM	<b>Client Name</b>	Bandipora Collection	<b>Specimen Received</b>	28/05/19
<b>Age/Sex</b>	38 YRS/F		Centre, Jammu & Kashmir	<b>Specimen Type</b>	Tissue
<b>Patient ID</b>	011905240004	<b>Client Code</b>		<b>Collection Date</b>	28/05/19
<b>Specimen ID</b>	MOLQ/B-960/19	<b>Ref. Doctor</b>	HEALTH CREASANT	<b>Report Date</b>	30/05/19

## SURGICAL PATHOLOGY REPORT

### Gallbladder

#### DIAGNOSIS

**CHOLECYSTITIS WITH CHOLELITHIASIS**



#### **SPECIMEN**

Gallbladder

#### **GROSS**

Received 5.9x2.3cm long gallbladder cut section shows stones.

#### **Microscopy**

Section examined shows ulcerative mucosa and Rokitansky-Aschoff sinuses (irregularly shaped tubular structures lined by cuboidal lining epithelium with round to oval nucleus) with fibro collagenous tissue and inflammatory cells (lymphocytes).

**Note :** All biopsy specimen will be stored for 15 (fifteen) days, block and slides for 5 (five) years only from the time of receipt at the laboratory. No request, for any of the above, will be entertained after the due date.

#### **Reference**

- i) Rosai and Ackerman's Surgical Pathology.
- ii) Modern Surgical Pathology.

**Gulshan Yadav, MD**  
Consultant Pathologist