

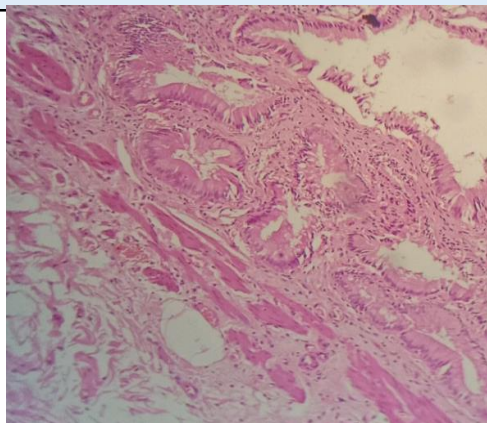
Patient Name	Ms. RITU SONI	Client Name	Polaris Hospital	Specimen Received	23/05/19
Age/Sex	42 YRS/F	Client Code	MolQ1967CW	Specimen Type	Tissue
Patient ID	011905230193	Ref. Doctor		Collection Date	23/05/19
Specimen ID	MOLQ/B-945/19			Report Date	29/05/19

SURGICAL PATHOLOGY REPORT

Gall bladder

DIAGNOSIS

CHOLECYSTITIS WITH CHOLELITHIASIS



SPECIMEN

Gall bladder

GROSS

Received 7.1x3.2cm long gal bladder cut section shows stones.

Microscopy

Section examined shows ulcerative mucosa and rokitansky aschoff sinus (irregularly shaped tubular structures lined by cuboidal lining epithelium with round to oval nucleus) with fibro collagenous tissue and inflammatory cells (lymphocytes).

Note : All biopsy specimen will be stored for 15 (fifteen)days, block and slides for 5(five) years only from the time of receipt at the laboratory. No request ,for any of the above ,will be entertained after the due date.

Reference

- i) Rosai and Ackerman's Surgical Pathology.
- ii) Modern Surgical Pathology.

Gulshan Yadav, MD
Consultant Pathologist