

Patient Name	Mr. HEMANT(31385)	Client Name	Pushpanjali Hospital	Specimen Received	22/05/19
Age/Sex	18 Years/Male	(Rewari)		Specimen Type	Tissue
Patient ID	011905220301	Client Code	MolQ1789CM	Collection Date	22/05/19
Specimen ID	MOLQ/B-933/19	Ref. Doctor	DR.MUKESH	Report Date	29-Oct-2018

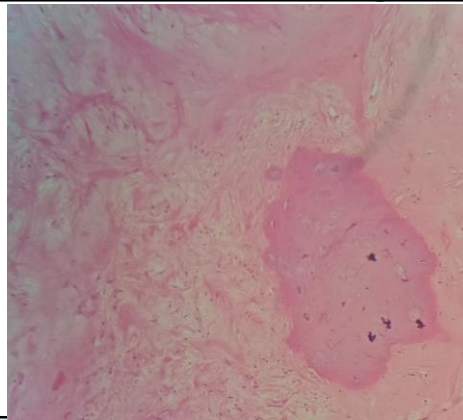
SURGICAL PATHOLOGY REPORT

Thigh swelling

DIAGNOSIS

Benign myofibroblastic lesion

Kindly co-relate with clinical and radiological finding.



SPECIMEN

Thigh swelling

GROSS

Received 10x6cm greyish white lobulated tissue piece cut section shows bony calcified area.

Microscopy

Section examined shows cellular stroma with fibro collagenous tissue, mature bony trabeculats with osteocytes and few myofibrocbantic.

No atypical cells seen.

Section also shows mononuclear inflammatory cells with muscle bundles

Note : All biopsy specimen will be stored for 15 (fifteen)days, block and slides for 5(five) years only from the time of receipt at the laboratory. No request ,for any of the above ,will be entertained after the due date.

Reference

- i) Rosai and Ackerman's Surgical Pathology.
- ii) Modern Surgical Pathology.

Gulshan Yadav, MD
Consultant Pathologist