

Patient Name Miss. SHANU W PORA
Age/Sex 23YRS/F
Patient ID 011905210076
Specimen ID MOLQ/B-937/19

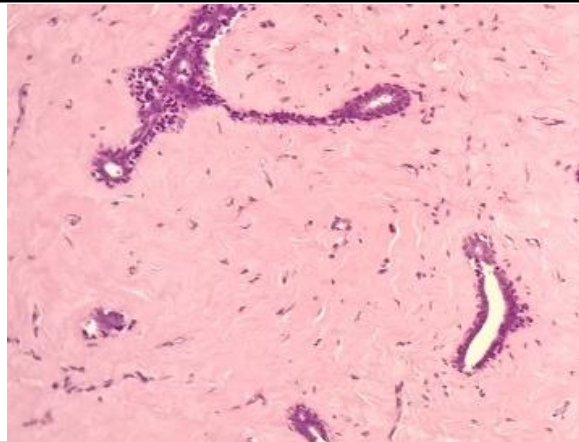
Client Name Tantray Labs, Jammu & Kashmir
ReferBy

Specimen Received 21/05/19
Specimen Type Tissue
Collection Date 21/05/19
Report Date 30/05/19

SURGICAL PATHOLOGY REPORT

Fibroadenoma of right breast

Benign breast lesion.



SPECIMEN

Fibroadenoma of right breast

GROSS

Received 5x4cm greyish white tissue piece.

Microscopy

Section examined shows cystically dilated ducts with cuboidal epithelium with small round nucleus surrounded by fibro collagenous tissue. No granuloma seen. No malignant cells seen.

Note : All biopsy specimen will be stored for 15 (fifteen) days, block and slides for 5 (five) years only from the time of receipt at the laboratory. No request for any of the above, will be entertained after the due date.

Reference

- i) Rosai and Ackerman's Surgical Pathology.
- ii) Modern Surgical Pathology.



Gulshan Yadav, MD
Consultant Pathologist