

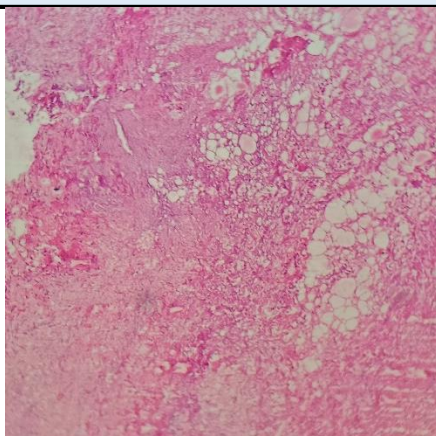
<b>Patient Name</b>	Ms. ANAMIKA	<b>Client Name</b>	Kriti Healthcare	<b>Specimen Received</b>	18/05/19
<b>Age/Sex</b>	13 YRS/F	<b>Client Code</b>		<b>Specimen Type</b>	Tissue
<b>Patient ID</b>	011905180167	<b>Ref. Doctor</b>		<b>Collection Date</b>	18/05/19
<b>Specimen ID</b>	MOLQ/B-899/19			<b>Report Date</b>	27/05/19

## SURGICAL PATHOLOGY REPORT

### Parasitic cyst

#### DIAGNOSIS

**Parasitic( cysticercosis) infestation with inflammation.**



#### SPECIMEN

Parasitic cyst

#### GROSS

Received two 1x1cm greyish white tissue piece.

#### Microscopy

Section examined shows fibro collagenous tissue, inflammatory cells ( lymphocyte, macrophages, polymorphs). Section also shows ? degenerated membranous tissue, cystic cavity with duct like invagination with eosinophilic membrane.

No granuloma and no malignant cells seen.

**Note :** All biopsy specimen will be stored for 15 (fifteen)days, block and slides for 5(five) years only from the time of receipt at the laboratory. No request ,for any of the above ,will be entertained after the due date.

#### Reference

- i) Rosai and Ackerman's Surgical Pathology.
- ii) Modern Surgical Pathology.

**Gulshan Yadav, MD**  
Consultant Pathologist