

Preeti
Nijhawan



BA Continuum India Pvt. Ltd.

Anglo-Bank subsidiary of Bank of America Corporation

CERTIFICATE OF MEDICAL FITNESS


This is to certify that I have conducted the clinical examination

of Preeti Nijhawan on 10/05/2019

After reviewing the medical history and on clinical examination it has been found that he/she is

	Tick
<ul style="list-style-type: none">• Medically Fit	<input checked="" type="checkbox"/>
<ul style="list-style-type: none">• Fit with restrictions/recommendations <p>Though following restrictions have been revealed, in my opinion, these are not impediments to the job.</p> <ol style="list-style-type: none">1. <u>Thalassaemia minor (Hb)</u>2. <u>Plantar fasciitis</u>3. _____ <p>However the employee should follow the advice/medication that has been communicated to him/her. <u>Follow up E over 2 weeks</u></p> <p>Review after _____</p>	
<ul style="list-style-type: none">• Currently Unfit. <p>Review after _____ recommended</p>	
<ul style="list-style-type: none">• Unfit	

Dr. _____



Dr. RAKESH SHARMA

Medical Officer (Sr. Consultant)

The Apollo Clinic, (Location)
Chennai

This certificate is not meant for medico-legal purposes

विवेकानन्द आरोग्य केन्द्र

466 P, सेक्टर 12 A, नजदीक माधव भवन, गुरुग्राम
(भारत विकास परिषद् महाराणा प्रताप न्यास, गुरुग्राम द्वारा संचालित)



सुविचार

Ref. No.:

Date:

Name of patient: Mrs. Preeti Nijhwar	Age: 40	M/F: F
Consultant:	Speciality: Package	
MR No : MR006772	Visit No: OP013910	Date: 10-05-2019

Height - 155 cm

Weight - 55 kg

BMI - 22.9

Bp - 112/70 mmHg

Pulse - 88/min regular

G/I

RAO - (+)

Icterus -] nil
oedema]

lymphadenopathy - nil

Eye / Ear /

chest - clinically normal

Abdomen - soft

liver - not enlarged

spleen - not palpable

vision - Disturb - 6/6 (5) m
E glasses
near vision faulty

Fit natural relapse

Ho Thalesia nil

No Ho anaemia in alcohol or tobacco.

Ho pain @ side of 5 year

Observation :

- ① Thalesia nil
- ② Diminution of near vision
- ③ Peritonitis?

Dr. Arun

Dr. Arun

विवेकानन्द आरोग्य केन्द्र

डायग्नोस्टिक, रायबोरेटिक एवं रेवीडी
बस स्टेशन रोड, मंगलूरु जंक्शन - ५७५ ००१



Radiology Report

Name : Mrs. Preeti Nijhawan
Age/Gender : 40 Y/F
Prescribed Doctor : Self

MR No : MR006772
Visit ID : OP013910
Report Date : 10-05-2019 10:12

Ultrasound

USG EXAMINATION : WHOLE ABDOMEN

Liver shows normal shape and size with homogenous echo texture. Intrahepatic biliary radicals are not dilated. No focal lesion is seen. **Portal Vein** shows normal calibre.

Gall bladder shows physiological distension and normal wall thickness. No calculus or mass is seen in the lumen.

CBD is normal in diameter. No calculus is seen

Pancreas is normal in size, shape and echo texture.

Spleen is normal in shape, size and echo texture.

Right kidney show normal shape & size. Cortico-medullary differentiation is maintained. Right kidney show no calculus or hydronephrosis. Right kidney measures 97 x 34mm.

Left kidney show normal shape & size. Cortico-medullary differentiation is maintained. Left kidney show no calculus or hydronephrosis. Left kidney measures 100 x 40mm.

Urinary bladder is over distended and is normal shape and size with normal wall thickness. No mass or calculus is seen.

Uterus shows normal shape, size and echo texture. No focal lesion is seen. Uterus measures 77 x 45 x 44mm. Endometrial thickness is 8.3mm.

Adnexae and Ovaries show no mass.

Right ovary measures 27 x 18mm.


Left ovary measures 24 x 13mm.

Vulva-de-sac is clear.

No evidence of mesenteric lymphadenopathy is seen.

Minimal inter bowel free fluid is seen.

Kindly correlate clinically.


Dr. Pinjun-foon
MD (Radio- diagnosis)

Radiology Report

Name : Mrs. Preeti Nijhawan
Age/Gender : 40 Y.F
Prescribed Doctor : Self

MR No : MR006772
Visit ID : OP013910
Report Date : 10-05-2019 15:39

X-Ray

X-RAY CHEST PA VIEW


Bilateral lung fields appears to be clear. No obvious pulmonary parenchymal lesion is seen.
Trachea is central.

Cardiac configuration appears to be normal with normal cardio-thoracic ratio.

Both costo phrenic angles and domes of diaphragm are normal.

Visualized soft tissue and bony thoracic cage appears to be normal.

PLEASE CORRELATE CLINICALLY.


DR. PAVAN JOON
MD (Radio-diagnosis)



विवेकानन्द आरोग्य केन्द्र

466 P. सेक्टर 12 A, नजदीक माधव भवन, मुख्यमार्ग
(आर्य समाज परिसर, गुरुग्राम, हरियाणा)

Ref. No.

Date:

MR NO	MR006772	AGE	40YRS
PATIENT'S NAME	MRS. PREETI NUHAWAN	SEX	FEMALE
REF. BY		DATE	10.05.2019

BILATERAL MAMMOGRAPHY

Cranio-caudal and oblique views taken of both breasts.

The study reveals :

Breast parenchyma shows normal echo texture.

Skin and subcutaneous tissue appear normal.

Nipple areola complex appears normal.

No architectural distortion, mass lesion or abnormal calcification is noted.

Note is made of accessory breast in left axilla.

IMPRESSION:- FEATURES REVEAL NORMAL STUDY.

Note is made of accessory breast in left axilla.

DR.S.B. GANDHI
MD (Radio-diagnosis)



विवेकानन्द आरोग्य केन्द्र

466 P, सेक्टर 12 A, नजदीक गांधी बाजार, मुम्बई

उपरोक्त विवरण ECHO-REPORT मुम्बई द्वारा उपलब्ध



NAME	MRS. PREETI NIJHAWAR	AGE/SEX	40/F
UHID	006772	HOSPITAL NO.	OPD
REF. BY	HEALTH CHECK UP	DATE	10.05.2019

PROCEDURES : M-MODE / 2D / DOPPLER / COLOUR CONTRAST B.B.A. M2
MEASUREMENTS :

		NORMALS
Aortic Root Diameter	1.9	2.0-3.7 cm < 2.2 cm/M2
Aortic Valve Opening		1.5-2.6 cm
Right Ventricular Dimension		0.7-2.6 cm < 1.4 cm/M2
Right Ventricular Thickness		0.3-0.9 cm
Left Atrial Dimension	2.7	1.9-4.0 cm < 2.2 cm/M2
Left Ventricular ED Dimension	3.1	3.7-5.6 cm < 3.2 cm/M2
Left Ventricular ES Dimension	4.4	2.2-4.0 cm
Interventricular Septal Thickness	0.7ED ES	0.6-1.2 cm
Left Vent PW Thickness	0.6ED ES	0.5-1.0 cm
IVS / LVPW		

INDICES OF LEFT VENT. FUNCTION

Mitral E-Septal separation		<0.9 cm
Minor axis		24.42%
LV Ejection Fraction	60%	55-65%

IMAGING:

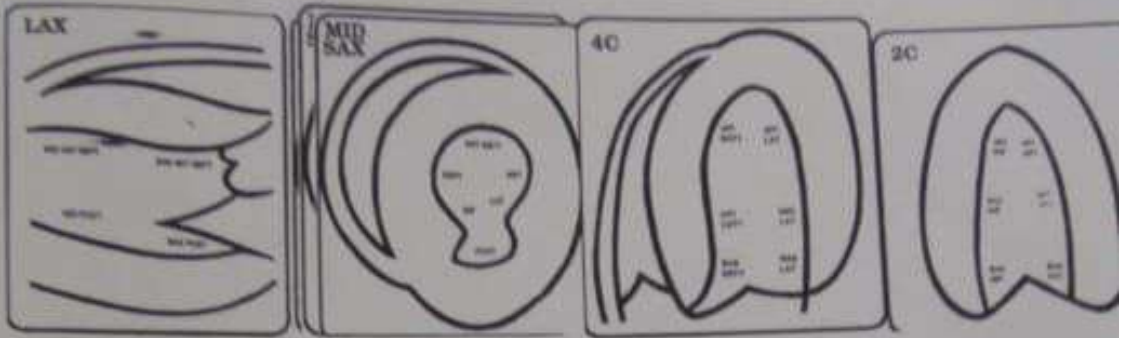
M-Mode examination revealed normal movement of both mitral leaflets during diastole. No SAM or mitral valve prolapse is seen. Aortic cusps are not thickened and closure line is central. Tricuspid valve is normal. Pulmonary valve is normal. Aortic root is normal in size. Dimension of left atrium and left ventricle are normal. No LVH present.

2-D imaging in PLAX, SAX and apical views revealed a normal sized left ventricle. Movement of septum, inferior, anterior, posterior and lateral walls is normal. Global LVEF is 60%. Mitral valve opening is normal. No evidence of mitral valve prolapse is seen. Aortic valve has three cusps and its opening is not restricted. Tricuspid valve leaflets move normally. Pulmonary valve is normal. Interatrial and interventricular septa are intact. No intracardiac mass or thrombus is seen. No pericardial pathology is observed.

सम्पर्क सूत्र: (0124-2224102 / 103 / 104 | Mob.: 8683061905, 8683061906

* Not for Medico Legal Purpose*

LV WALL MOTION



DOPPLER

MV	-	E = cm/sec	MR	Nil
		A = cm/sec		
AV	-	cm/sec	AR	Nil
TV		cm/sec	TR	Nil
PV		cm/sec	PR	Nil

COLOUR FLOW

Normal colour flow

FINAL DIAGNOSIS:

2D Colour Doppler Exam of Mrs. Preeti Nijhawar revealed:

1. No regional wall motion abnormalities seen in resting state. LVEF - 6
2. No LVH. All cardiac chambers dimensions are normal.
3. All valves are normal.
4. Normal left ventricular function.
5. No intracardiac mass or thrombus
6. No pericardial pathology seen. No clot /veg seen.

DR. ASHISH GUPTA

Dr. ASHISH GUPTA
 MBBS, MD(Medicine), DM(Cardiology)
 Consultant Cardiology
 Vivekanand Arogya Kendra
 Regn. No. HMC-10365

विवेकानन्द आरोग्य केन्द्र

466 P, सेक्टर 12 A, लजदीक माधव भवन, गुरुग्राम
(भारत विकास परिषद् महारणा प्रताप न्यास, गुरुग्राम द्वारा संचालित)



रुविघाए

Ref. No.:

Date:

Name of patient: Mrs. Preeti Nijhwar	Age: 40	M/F: F
Consultant:	Speciality: Package	
MR No : MR006772	Visit No: OP013910	Date: 10-05-2019

Routine checkup 11/5/19.

P/S - Cx Enoxia

Adv

Ph - Cx blends on Temu
Cx irregular

Pap smear
taken for
goblet

Wt-Aw mp S

flw E

Blut sp

repat

10/5/19

Adv

Pap smear
inflammatory
smear

0-1-0 Doxy
100mg
W x 7 days

0-1-0 Voveran
17 x 50mg

0-1-0 metrogyl
400mg

2ml 1% Jil Pan-D
00 x 7 days