

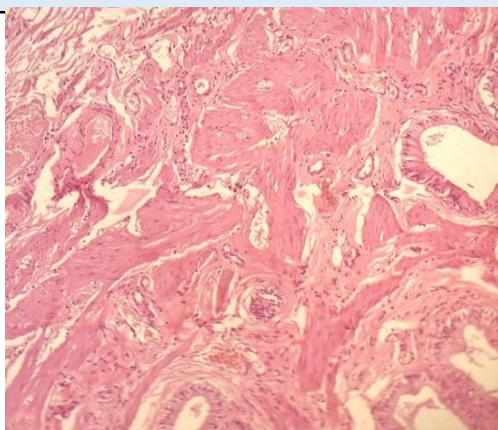
<b>Patient Name</b>	AASHYBI	<b>Client Name</b>	Murad Hospital, Nuh	<b>Client Specimen Received</b>	23/05/2019
<b>Age/Sex</b>	29 YRS/F	<b>Code</b>		<b>Specimen Type</b>	Tissue
<b>Patient ID</b>	011905230288	<b>Ref. Doctor</b>	C/O VARDHAN NURSING	<b>Collection</b>	23/05/2019
<b>Specimen ID</b>	MOLQ/B-941/19	<b>HOME PALWAL</b>		<b>Report Date</b>	25/05/2019

## SURGICAL PATHOLOGY REPORT

### Gall bladder

#### DIAGNOSIS

**CHOLECYSTITIS WITH CHOLELITHIASIS**



#### **SPECIMEN**

Gall bladder

#### **GROSS**

Received 6x6.5cm long gall bladder cut sections shows stones.

#### **Microscopy**

Section examined shows ulcerative mucosa and Rokitansky-Aschoff sinus (irregularly shaped tubular structures lined by cuboidal lining epithelium with round to oval nucleus) with fibrocollagenous tissue and inflammatory cells (lymphocytes).

**Note :** All biopsy specimen will be stored for 15 (fifteen) days, block and slides for 5 (five) years only from the time of receipt at the laboratory. No request, for any of the above, will be entertained after the due date.

#### **Reference**

- i) Rosai and Ackerman's Surgical Pathology.
- ii) Modern Surgical Pathology.

**Gulshan Yadav, MD**  
Consultant Pathologist