

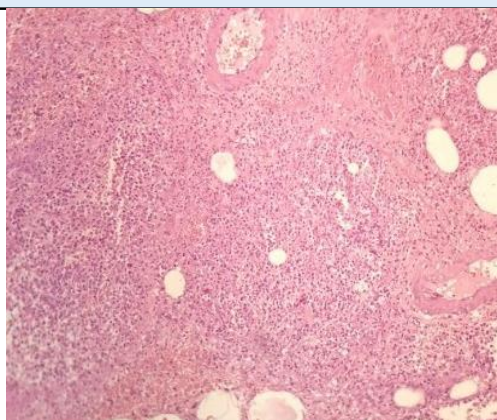
| | | | | | |
|---------------------|------------------|--------------------|---------------------|--------------------------|------------|
| Patient Name | Ms. NUTAN | Client Name | Chiranjeev Path Lab | Specimen Received | 22/05/2019 |
| Age/Sex | 23 Years/Female | Client Code | MOLQ1019P | Specimen Type | Tissue |
| Patient ID | 011905220127 | Ref. Doctor | | Collection | 22/05/2019 |
| Specimen ID | MOLQ/B-931/19 | | | Report Date | 25/05/2019 |

SURGICAL PATHOLOGY REPORT

Appendix

DIAGNOSIS

ACUTE APPENDICITIS



SPECIMEN

Appendix

GROSS

Received 6.5x1.1cm greyish white tissue piece.

Microscopy

Section examined shows lymphoid follicles with ulcerative mucosa. Deeper tissue shows inflammatory cells (polymorphs, lymphocytes and few histiocytes).

Note : All biopsy specimen will be stored for 15 (fifteen)days, block and slides for 5(five) years only from the time of receipt at the laboratory. No request ,for any of the above ,will be entertained after the due date.

Reference

- i) Rosai and Ackerman's Surgical Pathology.
- ii) Modern Surgical Pathology.

Gulshan Yadav, MD
Consultant Pathologist